

- Disease among young Grouse." P. Z. S. 1910, pp. 672-691, 4 plates.
- FANTHAM, H. B. (1910).—"Experimental Studies on Avian Coccidiosis, especially in relation to Grouse, Fowls, and Pigeons." P. Z. S. 1910, pp. 708-722, 1 plate.
- KLEIN, E. (1892).—"The Etiology and Pathology of Grouse Disease and Fowl Enteritis."
- MORSE, G. B. (1908).—"White Diarrhœa of Chicks." Circular 128, U.S. Dept. Agriculture, Bureau of Animal Industry.
- TEGETMEIER, W. B.—'Field,' vol. 104, p. 561 (24/9/04); vol. 105, p. 1027 (17/6/05); vol. 106, p. 410 (26/8/05); vol. 107, p. 465 (24/3/06).

6. On the Alimentary Tract of certain Birds and on the Mesenteric Relations of the Intestinal Loops. By FRANK E. BEDDARD, M.A., F.R.S., F.Z.S., Prosector to the Society.

[Received March 1, 1910 : Read November 29, 1910.]

(Text-figures 9-28.)

For some time past I have been accumulating notes relative to the viscera of birds which have died in the Society's Gardens, and have paid special attention to the alimentary tract. In the following pages I call attention to the intestinal tract of a number of birds which either have not been studied or as to which my own investigations lead me to disagree with earlier statements.

I have dealt more particularly with such species as have not been carefully studied from the point of view of the convolutions of the intestine, and am able to call attention to a considerable series of birds. The subject is by no means a new one, dating as it does from the accurate though few observations of John Hunter. I arrive, however, at rather different classificatory conclusions from others, and venture therefore to direct the attention of the Society not only to the new facts but also to certain classificatory inferences to which these facts point.

The observations which I lay before the Society may be considered under the following headings, viz. :—

- § Historical Survey, p. 48.
- § Description of the Intestinal Tract in various Groups of Birds, p. 50.
- § Some General Considerations. p. 86.
- § The Primitive Form of the Intestine in Birds, p. 86.
- § The Course of the Evolution of the Gut, p. 87.
- § The Mutual Affinities of Avian Families judged by the Intestinal Convolutions, p. 89.
- § The Relationship between the Gut and the Nature of the Food, p. 90.
- § Summary of Facts relating to the Intestinal Coils of Birds. p. 92.

§ *Historical Survey.*

There is no doubt that the fullest general account of the intestinal tract of birds written by the older anatomists is that of John Hunter*. He examined and annotated upon more than fifty species not wholly though mainly British. His observations are entirely correct, though not always quite full enough. In many cases, however, he has seized the main features of the intestinal coils so accurately and sufficiently that but little in the way of addition is needed. Thus in the Gallinaceous birds he has appreciated the loose arrangement and absence of fixed loops in the postduodenal section of the small intestine and the attachment of its terminal region to the duodenum. In the Rails he has correctly described the three distinct loops of the jejunal region and the attachment of the first and third of these together. In the Accipitres the short loop just above the cæca is described in many forms. The peculiarities of the Parrot intestine are fully described. In short, Hunter accomplished a great deal.

Cuvier and Duvernoy † distinguished perfectly correctly, as Dr. Mitchell has pointed out, the three separate regions in the small intestine of a bird, which I propose to call duodenal, jejunal, and ileic loops, and they also indicated the fact that the middle of the three loops is frequently folded upon itself, contorted into a spiral, or subdivided into several regions. Furthermore, it is remarked (and I find myself in accord with this opinion) that, “le canal intestinal des *oiseaux* est loin de présenter des différences aussi nombreuses, d’une espèce, d’un genre ou d’une famille à l’autre, que celui des mammifères.” Thereafter follows a considerable amount of detail concerning these different loops in the different groups of birds. For example, the three simple loops of the Passerines are referred to in a good many species and the spiral arrangement of the middle or jejunal loop is described in the Crows. The Picarian birds, Touracou and Cuckoo, are described in such words as to show that they agree completely with the Passerines. Cuvier did not, however, as Dr. Mitchell has also and quite justly pointed out, delimit the middle region correctly. He describes the limits of the third (and last) region of the small intestine as indicated sometimes on the side of the middle loop by an unpaired cæcum (*i. e.*, Meckel’s diverticulum). This is never the case, I believe ‡.

In his ‘Lectures on Comparative Anatomy,’ Sir Everard Home § has figured the coils of the small intestine in a number of birds—for instance, the Raven, where the spiral of the jejunum and the close association of the ileic and duodenal loops are indicated; the

* ‘Essays and Observations,’ ed. by R. Owen, vol. ii., London, 1861.

† ‘Leçons d’Anatomie comparée de Georges Cuvier,’ rec. et publ. par G. L. Duvernoy, t. iv. 2me partie. Paris. 1835, p. 269 *et seq.*

‡ But see for a possible exception the account of the Timamou below, p. 52.

§ ‘Lectures on Comparative Anatomy,’ London, 1814, vol. i. p. 402, vol. ii. pls. civ. cxvii. I am indebted to Dr. Mitchell for the exact reference to this more than once misquoted work.

Sea-niew, where the spiral is also shown, and it is remarked by the author that the turns of the intestine bear a close resemblance to those of the Crow, Swan, Goose, "*Ardea argala*," &c.—not a very long series of birds.

Owen, in describing the Flamingo *, pointed out that the small intestines "were disposed in twenty-one elliptical spiral convolutions, eleven descending towards the rectum and ten returning towards the gizzard in the interspaces of the preceding." The same anatomist correctly described the three loops in the small intestine of the Hornbill †. In the 'Comparative Anatomy and Physiology of Vertebrates' ‡ many more facts are given, most of which appear to be quite correct, but all are not quite intelligible to myself. Not many comparisons are made. The Cuckoo is correctly described, but it is not pointed out that it agrees with the Hornbill, which bird, indeed, is not referred to in the volume. The general prevalence of concentric folds among birds with long intestines is noted. The peculiarities of the Gallinaceous birds which have no fixed loops except the duodenal are appreciated in the description of the Common Fowl. The attachment of what I term the ileic loop to the gizzard and to the duodenal loop is mentioned.

Dr. Gadow's contributions § to the subject of the present communication have an importance of their own which is very great. But they do not come exactly within the limits of the discussion to which I desire here to contribute, since the aim of that anatomist was to portray the arrangement of the gut within the body-cavity and not to delimit only the permanent loops of the intestine as formed upon the supporting mesentery.

The most recent contributions to the subject known to me are by Dr. Chalmers Mitchell ||. In these memoirs, the author, in addition to discussing some parts of the subject with which I am not concerned here, deals with a much larger series of species than any previous author and has arranged his observations systematically, so as to cover most of the existing groups of birds. His special object, however, was to trace the various modifications of the intestinal tract to what he believed to be a primitive type, to arrange them in the form of a phylogenetic tree, and to see how far such a tree would agree with or correct conceptions of the phylogenetic ideas regarding birds as a whole. In the course of this paper I shall refer to various points in which my own observations do not agree with those of Dr. Mitchell. In my opinion, however, Dr. Mitchell's mode of figuring the intestinal tract of birds gives an appearance of simplicity which is misleading, with the result that birds which are separated by marked characters

* P. Z. S. 1832, p. 142.

† *Ibid.* 1833, p. 102.

‡ Vol. ii. 1866, p. 167 *et seq.*

§ "Vergl. Anatomie des Verdauungssystems der Vögel," Jen. Zeitschr. 1881. "On the Taxonomic Value of the Intestinal Convolutions in Birds," P. Z. S. 1889, p. 305; in Newton's 'Dictionary of Birds,' *sub voce* "Digestive System."

|| "On the Intestinal Tract of Birds, &c.," Trans. Linn. Soc. viii. 1903, p. 175; and an earlier paper in P. Z. S. 1896, p. 136.

are represented as being almost identical. In particular, Dr. Mitchell does not always distinguish between fixed loops, definitely formed by a narrow mesentery, and the irregular folds into which any mobile coil of the intestine may fall when disposed on the dissecting-board in Dr. Mitchell's fashion. I shall recur to definite instances in the course of this communication.

I shall now proceed to deal with the intestinal tract in a number of species of birds.

*§ Description of the Intestinal Tract in various
Groups of Birds.*

On opening the abdominal wall of most birds the intestine is usually seen to form a rather compacted mass, such as is figured, for example, by Dr. Gadow in most of the plates which illustrate his original memoir upon the intestinal tract in birds. This mass consists of parallel or concentrically arranged loops of intestine, and in the higher birds, such as a Heron, a Duck, or Stork, is very characteristic. This appearance of the gut distinguishes it at once from the Mammalian or Reptilian gut, where the intestine lies laxly within the abdominal cavity.

This also is the case with all the Struthious birds, whose intestinal tract at the first glance recalls that of a Mammal. A little disturbance of the apparently compact intestinal mass of some other birds, as, for instance, the Eagles and Hawks, shows that here, too, the intestinal tract is not really much welded together, but simply lies pushed close coil to coil, owing to the limited space in which it has to be stowed away. In other cases, however, it can be easily ascertained by the gentle pulling apart of the intestinal coils that the gut is disposed in tightly fixed loops.

This is the case, for instance, with Ducks, Storks, Penguins, and a variety of other genera and families. Inasmuch as the lax condition of the small intestine in such a bird as an Ostrich recalls that of the Mammalia and Reptiles, and is really like the intestinal tract in those Vertebrates, it is to be assumed that this condition of the bird's gut is the more primitive condition and that the specialisation into definitely fixed concentrically or parallel arranged loops, whether narrower or wider, is an index of the higher position of the bird in the series. I shall commence the following survey of such new facts as I have to add to the matter in hand by dealing with the more primitive groups of birds first. Indeed, I have not attempted in this paper to map accurately the coils in several families of birds where they are very complicated, such as the Stork tribe; for I am not satisfied as to the relationship of the coils in these birds to the more simple intestine of lower forms. It is almost entirely with the latter that I deal in the present communication to the Society.

Of the RALITÆ I have examined all the living genera. I fully agree with Dr. Mitchell as to the basal position in this group of

Casuarius and *Dromæus*, but I find his description defective in one particular and the illustration which he gives of *Casuarius* correspondingly inaccurate. It would be inferred from that figure * that the gut lay in a single line without any attachment between the ileum and duodenum; that—to use Dr. Mitchell's own term—there was no vestige of a supraduodenal loop. The existence of this attachment is indicated by him in other cases by a cut blood-vessel; there is no such "short circuit" represented in his figure of the Cassowary. Nevertheless, two species of Cassowary which I have dissected, viz. *C. australis* and *C. westermanni*, show such a connection, which is not, however, associated with the formation of an ileic loop distinguishable from the jejunum.

Nor can I agree with Dr. Mitchell's figure of *Apteryx*, unless, indeed, the species examined by him (*A. mantelli*) differs from that examined by myself (*A. australis*). For I find in the latter bird no definite ileic loop, but only an attachment by mesentery of the latter part of the ileum to the duodenum. The bird, in fact, exactly resembles *Casuarius*, *Struthio*, and the Gallinaceous birds in this particular.

In *Rhea americana* the intestine is formed upon a plan which may be interpreted in one of two ways—one of which is certainly not "archicentric" in the sense in which Dr. Mitchell uses the word, and the other interpretation hardly justifies the use of the word "archicentric." Since, in various other points of structure (*e. g.* less degeneration of wing, syrinx), *Rhea* is much less "Struthious" than *Casuarius*, it might be expected that the intestinal tract also would be more like that of Carinate birds. The accompanying figure (text-fig. 9, p. 52) shows the course of the intestine in a female example of *Rhea americana*, and may be compared with the figure drawn by Dr. Mitchell † from the intestinal tract of the same species, with which I do not find myself able to agree entirely. Dr. Mitchell, however, is perfectly right in distinguishing two loops only in the small intestine, viz., the duodenal and another which may or may not be the ileic loop of other birds, or "supraduodenal," as it is termed by him.

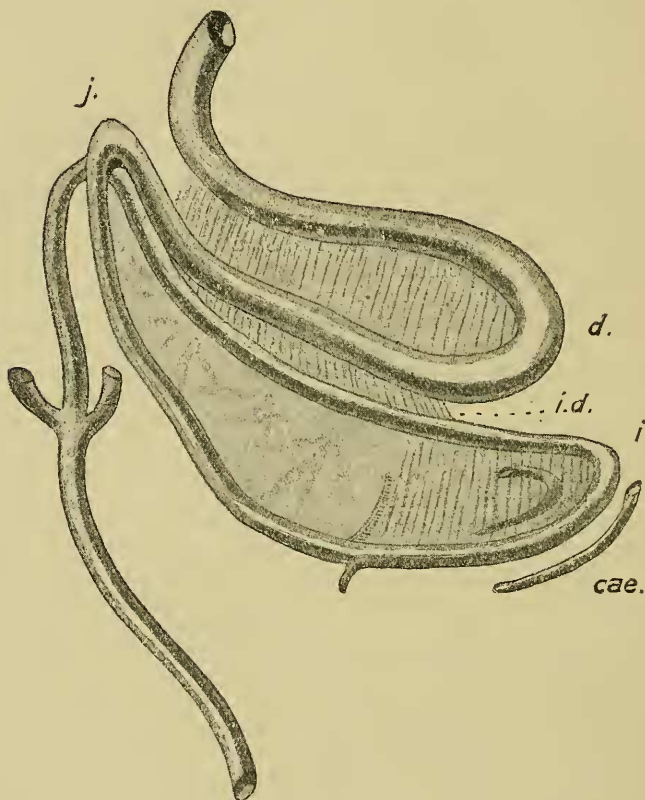
This latter loop is wider as well as longer than the duodenal loop, and it lies parallel with it as does the ileic loop (nearly always) in other birds, and is connected with the duodenal loop by the usual ileo-duodenal ligament, which is long and extends nearly to the end of the duodenal loop, while it is attached along more than half of the length of the loop now under consideration. So far the facts point towards the interpretation of this loop of the small intestine in *Rhea* as being the homologue of the ileic loop of other birds. If this interpretation be correct, then the jejunal region or loop will be practically absent and reduced merely to the small tract just where the lower limb of the duodenal loop bends round to join the lower limb of the (for the moment) alleged ileic loop. There is, I think, nothing intrinsically absurd in this

* P. Z. S. 1896, p. 140, fig. 3.

† Trans. Linn. Soc. *t. c.* p. 183, fig. 3.

suggestion; it is merely the assumption of the still further reduction of the jejunal region of the gut which is already greatly reduced in such birds as *Chunga burmeisteri* and *Houbara macqueeni*, where it is already as short as or even shorter than the ileic loop. There is another argument in favour of this interpretation of the two well-marked intestinal loops of *Rhea* which is derived from a

Text-fig. 9.

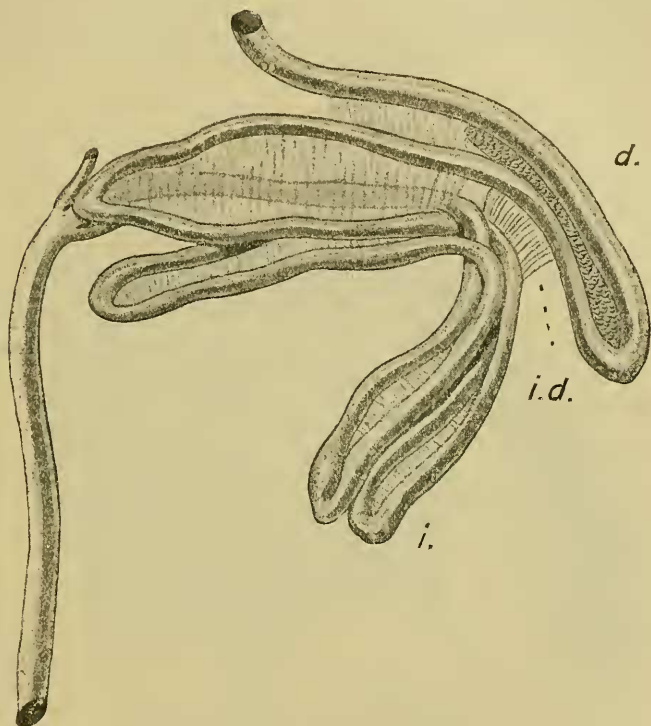
Intestinal tract of *Rhea americana*.

Cæ. Blind ends of caeca. *d.* Duodenal loop. *i.* Ileic region. *i.d.* Ileo-duodenal ligament. *j.* Jejunal region. In this and the succeeding figures the definite loops are marked by transverse lines.

consideration of the Tinamou, *Crypturus tataupa*. In the last-mentioned bird the intestinal loops are very remarkable; they are represented in text-fig. 10. There is nothing in particular to be said about the duodenal loop. This is followed by two loops, which lie one above the other; the proximal loop lying ventrally

to the more distal of the two. They are closely attached to each other and to the duodenal by ligament and cannot be freed without cutting or tearing. There is, in fact, every reason to regard these two loops as a subdivision of the usually single ileic loop. Moreover, the ileic loop is occasionally double in other birds; it is distinctly formed of two parallel loops in *Anthropoides paradisea* *.

Text-fig. 10.

Intestinal tract of *Crypturus tataupa*.

Lettering as in text-fig. 9.

It is to be noted also that the ventrally situated of the two subdivisions of the presumed ileic loop is attached up to nearly its end by ligament to the duodenal loop. There is no case known to me among birds where the jejunal loop is thus attached.

Another argument of the same kind is to be derived from a consideration of the intestinal tract of the Passerine *Ixocincla crassirostris*. In this Bulbul, of which I have dissected only one

* *Vide* p. 82.

example, the tract of the small intestine consists of two loops only, which are approximately equisized and are both rather wide. Furthermore, the two oval loops of gut are attached to each other along their whole length. It will be noted, therefore, that these two loops agree in all their characteristics with those of other Passerine and many Picarian Birds. But if this be so, it follows that the jejunal loop in this Passerine is reduced to the verge of disappearance. In any case, whatever be the interpretation of the several regions of the small intestine in *Ixocincla crassirostris*, it seems to me to be beyond all question that there is a very close likeness between its gut and that of *Rhea*, whether the likeness be superficial and due to parallelism of development or not.

Moreover, there is no bird known to me in which the jejunal loop has any intimate relations through ligaments with the ileic loop—at any rate, to anything like the degree which is exhibited in the case of *Crypturus tataupa*, on the view, of course, that the jejunal loop is represented. Finally—though naturally it is not attempted to lay any very great stress upon this piece of evidence—a particular relationship between the Tinamou and *Rhea* is by no means an unreasonable suggestion.

There is, however, an alternative view to be taken of the intestinal tract of *Rhea americana*. It will be observed that Meckel's diverticulum lies at about the middle of the lower limb of the loop which has been provisionally regarded as the ileic loop; the diverticulum lies nearer to the duodenum, *i. e.* above the ends of the two cæca. This fact would appear perhaps to militate against the view that has just been set forth with regard to the intestinal tract. For generally, at any rate, Meckel's diverticulum lies on the jejunal portion of the intestine and, in fact, at about the middle of the length of the entire small intestine.

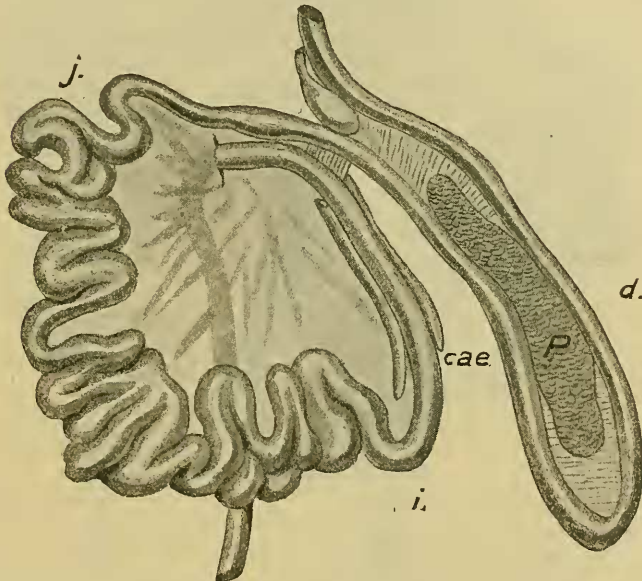
But although this may be *generally* the case in birds, it is by no means universally so. In *Dendrocygna discolor*, for example, I find Meckel's diverticulum to be very much nearer to the ileic loop than to the duodenal, *i. e.* to be not by any means in the centre of the jejunal region. This is also clearly the case with *Carpococcyx radiatus* as shown in Dr. Mitchell's figure*. There is thus no absolutely fixed position for Meckel's diverticulum within the jejunal region of the gut, though there are no positive facts which lead to the inference that this diverticulum may lie within the ileic area. If it be held that the existence of the diverticulum fixes the jejunal region of the gut, then the intestinal tract of *Rhea* is simply a slightly further development of that of *Casuarus* in the direction of the Gallinaceous birds and many Picopasserines when there is no actual loop formed in the ileic region, but merely an attachment by ligament to the duodenal loop.

The gut of the Ostrich has been described by Dr. Mitchell, as well as by others. I have only some small matters to add to the

* Trans. Linn. Soc. *t. c.* p. 243, fig. 60.

account by Dr. Mitchell in relation to the object of the present paper. The duodenal lobe of the example of *Struthio molybdophanes* has a lateral branch, as has the species examined by Dr. Mitchell. The pancreas extends down the duodenal loop to a point rather beyond this lateral diverticulum of the duodenal lobe. It does not, however, by a long way reach the end of the loop. It does, however, in *Apteryx*. The attachment of the ileum to the duodenal lobe is rather more marked than in Gallinaceous birds and much more marked than in *Apteryx*. The ligamentum ileo-duodenale reaches along the duodenal loop to a point beyond the posterior termination of the pancreas in that loop. I found no fixed loops either in the moderately long small intestine or in the longer colon.

Text-fig. 11.

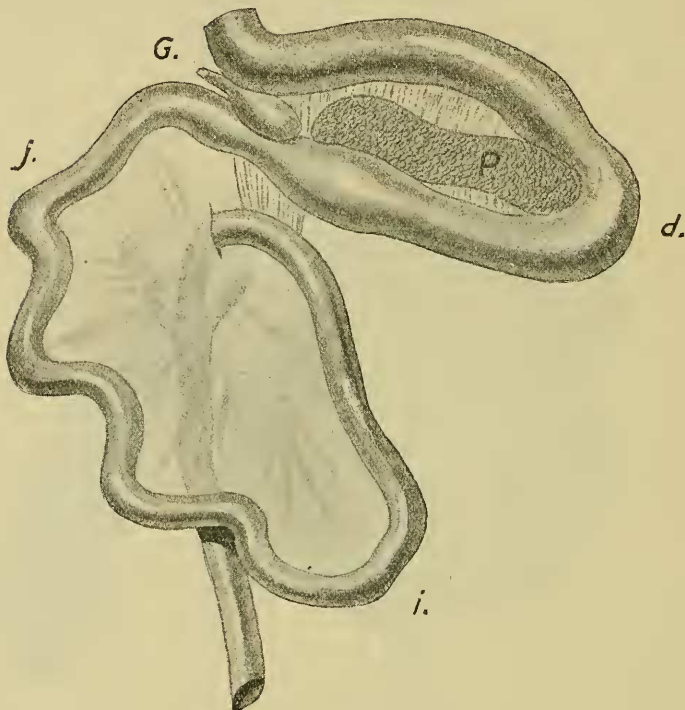
Intestinal tract of *Talegalla lathami*.

P. Pancreas. Other lettering as in text-fig. 9.

The GALLINACEOUS birds appear to be very uniform in the structure of the gut. I may take *Crax carunculata* as a type with which the very slight divergences shown by other Galli may be compared: the duodenal loop is long and very thick and the pancreas extends about halfway down it. The duodenum soon narrows to form the jejunal region, which is of considerable length and arranged in loose folds which can be straightened out and among which are no fixed loops. There is no sharp line of demarcation between the jejunal and the ileic region, which

later becomes a straight tract of intestine running partly parallel with the duodenum and attached to it just for a short space at the root of the duodenum where it (the ileum) bends upon itself to join the colon. A second species, a hybrid *C. globicera* and *C. heeki*, was absolutely identical in all the characteristics just given. The description of one species fits the characters of the other.

Text-fig. 12.

Intestinal tract of *Ortalis ruficauda*.

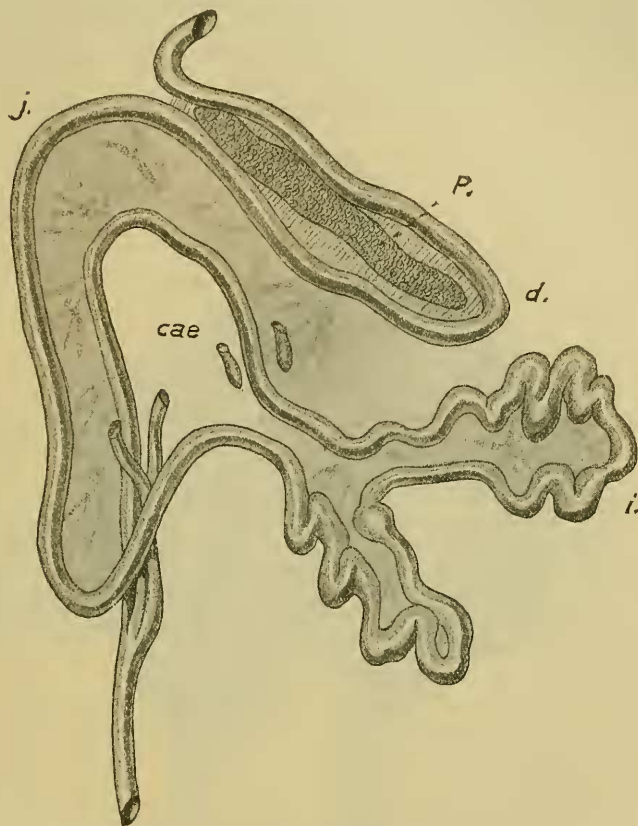
G. Gall-bladder. Other lettering as in text-figs. 9 & 11.

In *Talegalla lathamii* (text-fig. 11, p. 55) the only difference that I could detect was the further extension of the pancreas along the duodenal loop, the end of which, however, it does not reach.

Among the Phasianidæ I have examined a few species, and again find no differences of moment from other Gallinaceous birds. In *Thaumalea* (*picta* and *amherstiae*) the pancreas reaches to quite the end of the duodenal loop, and, as in other genera, the ileic end of the small intestine (there is, as in other forms, no definite ileic loop) is attached to the duodenal loop by

a not very long ileo-duodenal ligament. In *Eupsychortyx sonnini** the intestine is shorter, but its arrangement is precisely that of

Text fig. 13.

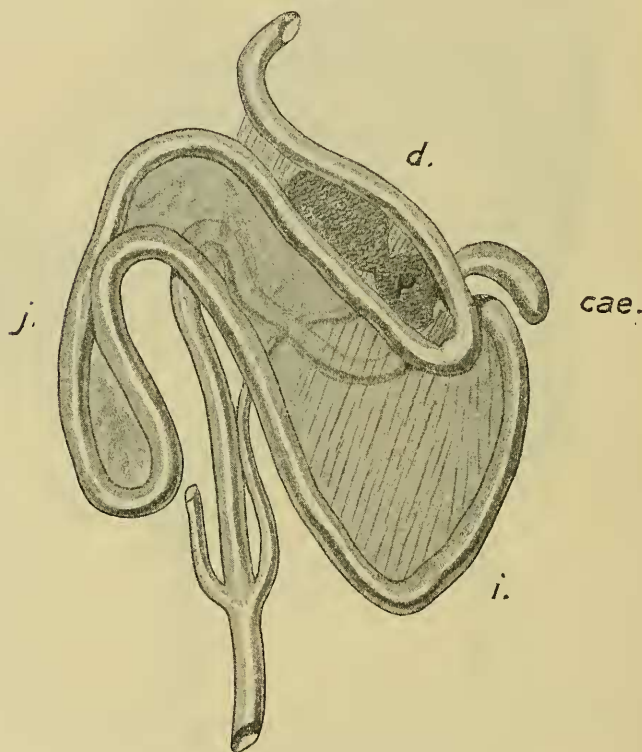


Intestinal tract of *Euplocamus nycthemerus*, showing condition reversed from the normal. Lettering as in text-figs. 9 & 11.

* The caeca of *Eupsychortyx sonnini* are remarkable in more than one way. When the body is opened these tubes are seen to lie in a tightly closed spiral or rather helicoid, producing at first the idea that it is the gut itself which is thus coiled. The spiral coiling of the caeca is not, however, permanent; they can be uncoiled and straightened with the exception of the very tip which remains coiled. Each caecum moreover, is seen to be covered with a network of bands in which a great deal of fat is laid down, and which forms a loosely meshed network with the long axis of the interstices corresponding to the long axis of the caecum. Blood-vessels traverse the strands and apparently form a corresponding network. I am disposed to compare this with the mass of short tubular blind outgrowths from the caeca in the Tinamou, *Calodromas* ('Ibis,' 1890, p. 61). A slight tightening of the bands referred to in *Eupsychortyx* would cause a bulging of the interstitial tracts and the consequent formation of such diverticula.

other Gallinaceous birds, and the pancreas extends quite to the end of the duodenal loop. *Penelope superciliaris* has also rather a short intestine and the pancreas extends to the end of the duodenal loop, thus showing that there is no distinction in this matter between the two groups of Gallinaceous birds. *Ortalis* (see text-fig. 12, p. 56) has also a very simple and short gut. I pass by a number of other genera that I have examined and which are

Text-fig. 14.

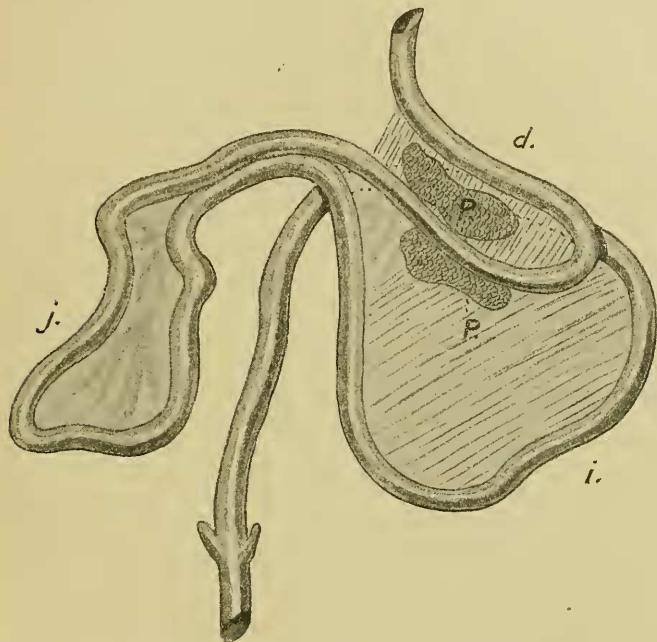
Intestinal tract of *Podargus cuvieri*.

Lettering as before.

quite like those already dealt with, to consider a remarkable variation shown by *Euplocamus nycthemerus*. In one specimen the typical Gallinaceous arrangement was to be seen; the calibre of the duodenum was much greater than that of the succeeding part of the small intestine and the pancreas extended to the very end of the duodenal loop. The terminal straight portion of the ileum was attached in the usual way by ligament to the

duodenal loop. In another specimen (text-fig. 13, p. 57) the disposition of the jejunal and ileic regions was exactly reversed*. The duodenal loop passed immediately into a straight descending limb bent sharply upon itself at its lower extremity, and then passed into a laxly coiled and rather long section of gut unattached anywhere to the duodenal loop and ended eventually in the colon. The laxly coiled region of the gut lay to the left side instead of to the right, and there was, in fact, in this individual an exact reverse of normal conditions.

Text-fig. 15.

Intestinal tract of *Gymnorhina leuconota*.

Lettering as before.

It is thus evident that the intestinal tract of the Gallinaceous birds is very uniform throughout the group and that it is constituted upon a primitive plan which is very little, if at all, in advance of that which characterises *Apteryx* among the Struthious birds. The only difference is, indeed, that the ileo-duodenal ligament is longer among the Gallinaceous birds—that more of the ileum is attached to the duodenum. But this condition is more than paralleled by *Struthio*, where, as already mentioned,

* I compare these later (p. 79) with the normal conditions occurring in *Fratercula*.

a considerable tract of ileum is attached by the ileo-duodenal ligament.

The PICARIAN BIRDS, Cuckoos, Tonracoos, and PASSERINES really form one group so far as their intestinal convolutions go. It is impossible, as I think, to distinguish between the Picarian *Podargus curieri** and the Passerine *Gymnorhina leuconota*, which may be compared and cannot be contrasted in the accompanying figures (text-figs. 14, 15, pp. 58 & 59). The salient features in these two cases appear to me to be the great width of the ileic loop (its extreme narrowness in *e.g.* the Parrots places them at the opposite end of the series) and the close mesenteric connection by the ileo-duodenal ligament of the two loops in question. The great width of the ileic loop in *Nyctidromus*, *Cypselus*, and *Trogon* can be inferred from Dr. Mitchell's figures†, though he does not, except in the case of *Cypselus*, identify the loop. These figures suggest undoubtedly the primitive gut of a Ratite or Gallinaceous bird; perhaps they are comparable with *Melanerpes*‡.

Furthermore, the total absence of specialised loops in the middle region of the small intestine is to be noted. Mitchell, as well as his predecessors in this field, has commented upon the spiral arrangement in certain Passeres, and has remarked upon the tendency to a spiral even where there is no actual regular spiral formation. This affects the middle or jejunal loop, and is greater in the Raven than in any other bird which Mitchell has described or I have examined. I found in that bird a spiral of no less than nine double turns, whereas Mitchell has figured much fewer in *Corvus capellanus*. A complete spiral of this kind is, however, not common among the Passeres. Besides the Crow tribe I know it only in the Tanager, *Euphonia violacea*. The tendency to a spiral I have observed in many Passeres, among which I may mention a number of Birds-of-Paradise which I have lately had the opportunity of studying: these are *Diphyllodes lunsteini*, *Paradisornis rudolphi*, *Paradisea raggiana*.

It seems to be universal or nearly so for the ileo-duodenal ligament to connect those two loops of the intestine along their whole lengths, and also for the pancreas to extend up to the very end of the duodenal loop. I have found both these characters to exist in *Loxia crassirostris*§, *Sycalis flaveola*, *Euphonia violacea*, *Graculus religiosus*, *Buceros cylindrica*, *Turdus migratorius*, *Ptilonorhynchus violaceus*, *Cassidix oryzivora*, and the first-named character in a number of other genera of which I happen to have no note as to the pancreas. Both these anatomical features seem likely to be characteristic of the Picopasseres generally, even if not universally found among the members of that order of Birds.

* I have examined two specimens of this bird.

† Trans. Linn. Soc. *tom. cit.* figs. 68, 69, 70.

‡ *V. infra*, p. 62.

§ A peculiarity of the gut of this Passerine has been already referred to, *v.* p. 53.

I have not met with many divergences among the Picopasseres from the typical structure.

One of the most abnormal types—if not the most abnormal—among the Picopasseres is the Ground Hornbill, *Bucorvus abyssinicus*. The duodenal loop is longish and the pancreas extends nearly to its end. It is perfectly free from the ileic loop, which is longer than it. The ileic loop, moreover, is indented at its free extremity and thus shows signs of being bent over upon itself. It is also considerably longer than the duodenal loop. As in other Picopasseres, the jejunal loop is more or less divided into two, and the distal loop of these two is attached to the outgoing limb of the ileic loop, which on its way to the colon is looped once in a way precisely like that shown among the Accipitres and in some other birds. These facts are particularly interesting, because they confirm current opinion as to the anatomical likenesses between the Hornbills and the Hoopoe. It is plain from Dr. Mitchell's figure * of the intestinal tract of that bird that *Upupa epops* agrees with *Bucorvus* in a number of the characters to which I have referred above. He figures the two loops of the middle part of the intestine and the small "supracæcal" loop, which latter is so characteristic a feature of *Bucorvus* as compared with other Picarian birds. He does not, however, advert to this loop by that name or compare it with the "kink" which he found in the Accipitres of both the Old and New World. Nor does he indicate a mesenteric attachment between the jejunal and ileic loops in *Upupa* such as I find in *Bucorvus*. It is impossible, moreover, to be certain from Mitchell's figure how far the ileic and duodenal loops are connected. Their entire mutual freedom in *Bucorvus* is an uncommon feature. Although Dr. Mitchell happens, as I think, to be wrong in remarking that the character of the gut does not unite the Hoopoes and Hornbills closely, he was perfectly right in making that statement from the facts before him. This is a further example of the difficulty of arriving at sound classificatory conclusions without an exhaustive knowledge of the facts.

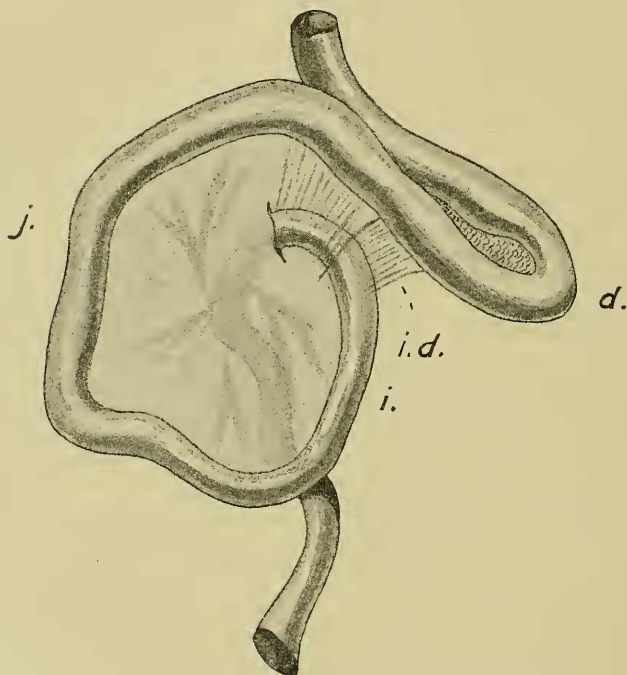
I have lately had the opportunity of examining the gut of *Upupa*, and can add something to the account given by Mitchell. It is a rather more abnormal member of the Picopasserine group than I had supposed. In my specimen there was no supracæcal kink. The duodenal loop was very wide (as Mitchell has remarked) and rather irregular in outline at its end, suggesting, therefore, a commencing spiral as in *Gypagus* and *Cathartes*—a fact which may be of some significance. The duodenal loop is larger than the ileic—precisely the reverse condition obtaining in *Bucorvus*. And while in *Bucorvus* there is no ileo-duodenal ligament, there is a short one in *Upupa* not nearly so extensive as in Picopasseres generally, and thus bridging over the gap between *Bucorvus* and its allies.

* Trans. Linn. Soc. t. c. p. 247, fig. 65.

The jejunum has certainly two definite loops and thus, agreeing with *Bucorvus*, differs from other Picopasseres. The pancreas in a most abnormal fashion extends into the first of these and is perhaps responsible for its formation.

It is, of course, possible that the intestinal tract of *Melanerpes superciliaris* differs from that of other Picidæ. But if it agree with that of the three species reported on by Dr. Mitchell, then I find myself in total disagreement with that writer as to

Text-fig. 16.

Intestinal tract of *Melanerpes superciliaris*.

Lettering as before.

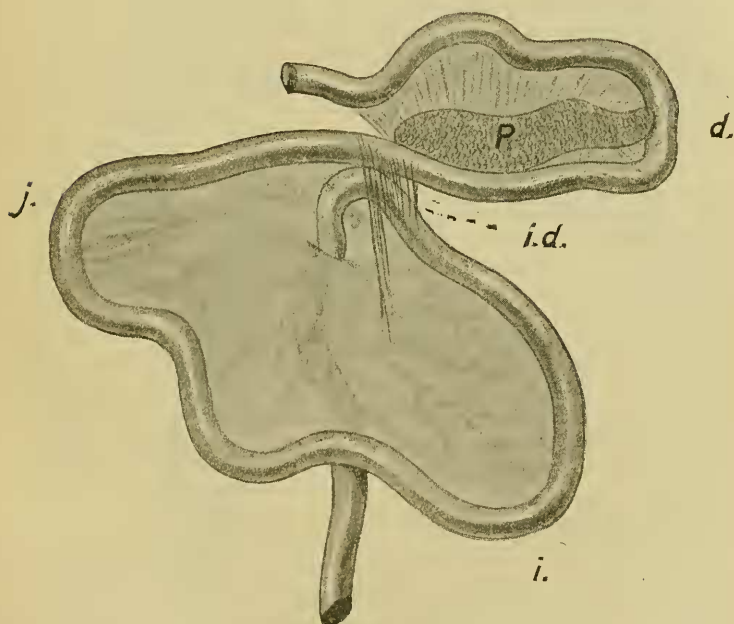
the relationships of the Woodpeckers. He observes of the Picidæ that "the conformation of the gut is in every important respect similar to that found in *Megascops*." I have not dissected *Megascops* for the purposes of the present communication, but I have examined three species of Toucans, of which family (Rhamphastidæ) Dr. Mitchell remarks that "Meckel's tract and the short rectum do not differ from the form found in *Megascops*." Now in *Megascops asiatica*, as is plainly shown in

Dr. Mitchell's figure *, there is a distinct ileic loop, which is wide as in Picopasseres generally. In the Toucans *Aulacorhamphus sulcatus*, *Rhamphastos ariel*, *Rh. carinatus*, there is also a perfectly distinct ileic loop a little less distinct than in some Picopasseres, but still distinct.

In *Melanerpes superciliaris* the only properly marked intestinal loop is the duodenal, down to the very end of which extends the pancreas. There is absolutely no ileic loop, as is shown in the figure (text-fig. 16). The jejunum simply passes forward and is connected by ligaments with the gizzard and with the duodenum quite far from the free end of the loop; it then turns abruptly backwards, passing straight to the cloaca.

The arrangement of the gut is, in fact, precisely that of the Gallinaceous birds, though, of course, the gut is shorter than that of most.

Text-fig. 17.



Intestinal tract of *Gecinus viridis*.

Lettering as before.

There is, indeed, no great disparity in length between the gut of *Melanerpes* and that of an equisized Gallinaceous bird, such as *Coturnix chinensis*. In view of the primitive nature of the palate as urged by Huxley and Parker, though not held by some

* Trans. Linn. Soc. *tom. cit.* fig. 71, p. 253.

others, the existence of a primitive type of gut is not without interest. There is in any case no doubt about their difference in this respect from their supposed allies the Rhamphastidæ, though it remains to be seen whether they are like Picarian birds of any other groups. These facts and considerations gain additional significance from the quite similar intestinal tract of *Gecinus viridis* (see text-fig. 17, p. 63).

Opinions undoubtedly differ as to the generic subdivisions of the family Alcedinidæ, but *Alcedo ispida* and *Halcyon sancta* have been placed in different genera—whether *Halcyon* or *Sauropatis*. The intestinal tract is, however, rather different in these two species, though one may be considered to be an exaggeration of the other. The simpler of the two is that of *Alcedo ispida*. In this Kingfisher the duodenal loop is free from the ileic for at least the greater part, and thus contrasts with most other Picarian birds. The jejunal region lies in a short spiral; but this spiral is not a permanent structure. It can be easily disarranged and spread out into an irregularly shaped loop. There is, in fact, no mesenteric connection between the circles of the spiral. The ileic loop is large, wide, and somewhat irregular, fully as long as the duodenal loop. The spiral of the jejunal region is, it should be added, quite a short one with only two complete turns.

In *Halcyon sancta* there are differences in nearly all of these features. The duodenal loop is, however, the same; it is a simple loop, not particularly wide, and the pancreas extends along it quite to its free end. I omitted to make any notes about the pancreas of *H. vagans*. The jejunal region of *Halcyon sancta* forms a spiral of eight limbs, and is thus, in the first place, much more complex than that of *Alcedo ispida*. In the second place, this spiral is fixed, and is a perfectly permanent structure which cannot be unwrapped without tearing the connecting sheets of mesentery. These are two important differences from the spiral found in *Alcedo ispida* and are, indeed, much greater differences than are known to me to exist between two species of any other genus. The condition of the jejunal section of the small intestine does not, however, exhaust the differences which eventually distinguish these two species of Kingfishers.

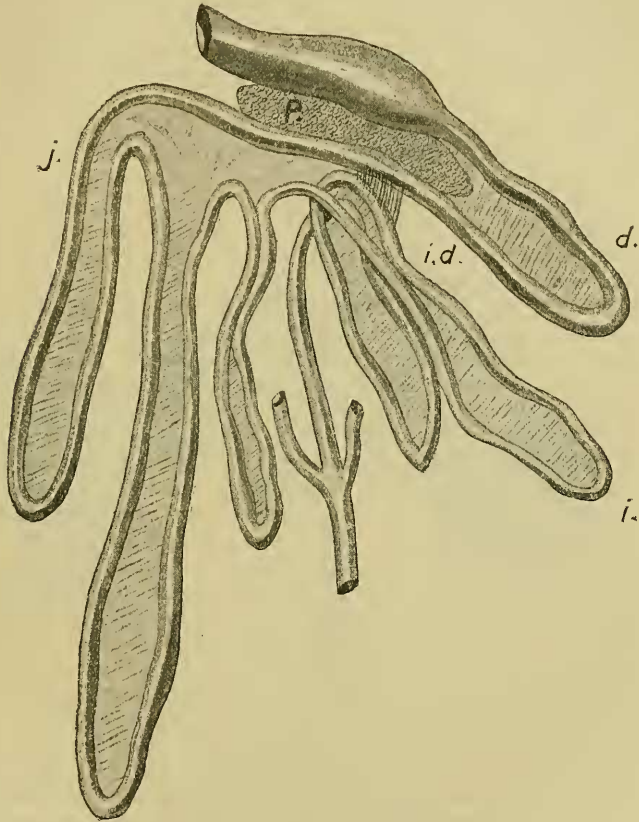
The ileic loop is, as in the last species, quite free from the duodenal; there is no ileo-duodenal ligament, except perhaps at the very base of the otherwise mutually free loops. The loop is, however, double, as it is, for example, in *Grus japonicus**, and as is shown in text-figure 18. Of these two loops, the proximal is the larger and is wide and somewhat irregular in form, and of about the same length as the duodenal. On the whole, it may, as I think, be admitted that the difference which the alimentary tract of this Picarian bird shows from that of other Picarian birds is actually greater than that which exists

* *Vide* p. 82.

between the Limicoline *Recurvirostra* and such a Passerine as *Euphonia*—in this case, two entirely different groups of birds.

Among the CUCULI I have examined only *Eudynamis orientalis*, which is one of the genera which does not seem to have been examined by previous writers from the present point of view.

Text-fig. 18.



Intestinal tract of *Grus japonicus*.

Lettering as before.

So far as I am able to say from the examination of this one type, Miss Marshall's figure* of *Geococcyx californianus* is a better representation of the characters of this group than that given by

* "Studies in Avian Anatomy.—II.," Trans. Texas Ac. Sci. ix. 1906, pl. ii. fig. 22.

Dr. Mitchell *. For the jejunal region possesses no definite loops and the gut, as a whole, is entirely like that of the majority of the Picopasseres. In *Eudynamis orientalis* the pancreas extends to the very end of the duodenal loop; the ileo-duodenal ligament also extends in its attachment to nearly the end of the duodenal loop. The ileic loop is, however, longer than the duodenal. In the jejunal region there are no specialised loops, and this part of the gut shows indications of a spiral arrangement.

Of the Musophagidæ I have examined two examples of *Turacus macrorhynchus* and one of *T. buffoni*. The two individuals of *T. macrorhynchus* agreed absolutely; the gut of *T. buffoni* differed very slightly from that of its congener. In *Turacus macrorhynchus* the duodenal and ileic loops were closely connected throughout their whole length by an ileo-duodenal ligament. The loops were moderately wide and of equal length or very nearly so. The jejunal loop is a little longer than either of the others and has a slight tendency to a spiral; when straightened out forcibly it lies in a Y shape with some slight rotation, as Hunter has figured in the case of *Scythrops novæ-hollandiæ* †. The pancreas, it should be observed, extends down to the very end of the duodenal loop. The only difference that I could detect in *Turacus buffoni* is that the ileic loop is rather longer than the duodenal. It is clear that the intestinal tract of these birds is precisely like that of the Cuckoos and of the majority of the Picopasseres.

Of the group HEMIPODI or TURNICES I have dissected two examples of the species *Turnix varia*. They were quite identical in the convolutions of the intestinal tract. The duodenal and the ileic loops were attached up to the end or very nearly so by an ileo-duodenal ligament. The loops were also fairly broad. The jejunal region of the gut lying between these two loops at either extremity of the canal was formed of a single loop, which had a tendency to twist itself into apparently two loops; but, without tearing or in any way interfering with the mesentery, this part of the gut could be moulded into the characteristic Passerine plan, as is shown in the accompanying figure (text-fig. 19). The pancreas extends right to the end of the duodenal loop. It is obvious from what has been said that this bird has a typically Passerine gut. It has not the faintest likeness to any Gallinaceous bird. Its likeness to many Passerines is shown by the fact that the pancreas extends down to the very end of the duodenal loop, and also by the breadth and connection up to the very end or nearly so of the ileic and duodenal loops as well as by the slightly spiral, and limited, jejunal loop.

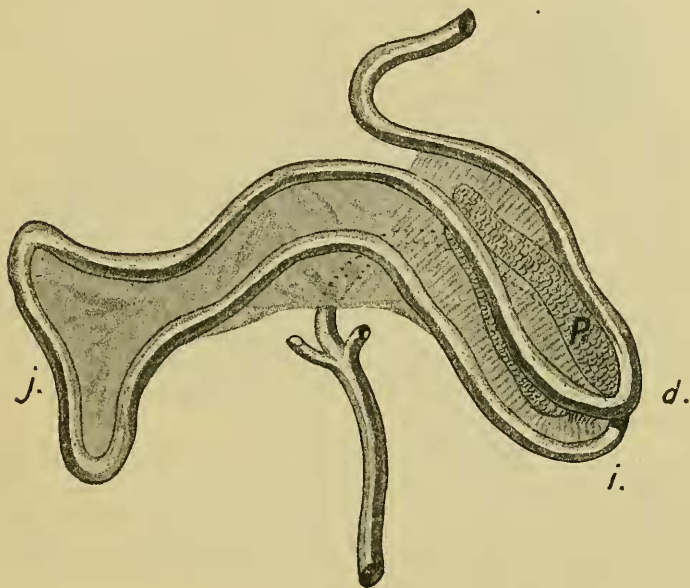
ACCIPITRES.—Among the Accipitrine birds which have not been examined by Dr. Mitchell I have dissected the Harpy Eagle, *Harpyhaliaëtus coronatus*. The duodenal loop is moderately wide and the pancreas does not extend far down it. The ileic loop is also fairly

* *Loc. cit.* p. 242, fig. 60.

† 'Essays and Observations,' vol. ii. p. 286.

broad, and contrasts very markedly with the duodenal loop, on account of the small calibre of the intestinal canal in this region; the duodenum is particularly wide and tapers off gradually towards the jejunum, the greater part of which is also very narrow; the tube is, in fact, quite as narrow here as is the ileum. The contrast between the duodenum and the commencement of the jejunum on the one hand, and the rest of the jejunum and the ileum on the other hand, is remarkably like that seen in the Gallinaceous birds, e. g., *Crax* (see p. 55). The ileic loop is as long as the duodenal loop or very nearly so. It is connected to it by a very short ileo-duodenal ligament, which leaves almost the whole of

Text-fig. 19.

Intestinal tract of *Turnix varia*.

Lettering as before.

both loops free of each other. The jejunal region is of considerable length, and lies loosely and irregularly folded in the body-cavity for the most part. The commencement of this part of the intestine, however, where it joins the duodenum is not only, as already mentioned, of greater calibre than the rest, but is fixed in a short and wide and therefore not very well-marked loop. The rest of this section of the intestine lies loosely like the Mammalian small intestine or the jejunum in Gallinaceous birds—that is to say, it has no fixed loops, but can be passed in a straight line between the fingers without tearing or distorting the mesentery which

supports it. Finally, between the ileic loop and the colon is a well-marked supracæcal fold, found in all Accipitrine birds and in some others. Of other Falconidæ I have examined the following species, which are not referred to in the memoir by Dr. Mitchell, viz. *Geranoaëtus melanoleucus*, *Astur palumbarius*, *Tinnunculus alaudarius*, *Astur approximans*, as well as one or two species that are referred to by him.

In *Astur palumbarius* and *A. approximans* the gut shows no marked differences from that of *Harpyhaliaëtus*, which I have taken as the type for this group. The pancreas extends but a short way along the duodenal loop, and the ileic loop is attached to the duodenal by a short ligament only at the base. The supracæcal loop is present, and the jejunum cannot be said to possess any pronounced folds independent of each other. As it lay in the body I noticed the formation of spirals in this region of the gut in *A. palumbarius*; but these were not permanent formations as in *Recurvirostra avocetta*. The whole of the jejunum could be straightened out bit by bit, the most pronounced fold, close to the duodenum, being large and wide and hardly comparable to the definite folds in the jejunum of more specialised birds, such as the Psittaci. *Geranoaëtus melanoleucus* shows again no salient differences; the supracæcal fold, however, is nearly as long as the ileic loop.

I agree with Dr. Mitchell in regarding the gut of *Falco* as being aberrant when compared with that of other Hawks and Eagles. The duodenal loop is, as he has said, irregular in form. I may add that the pancreas extends a good deal further down the duodenal than in the other Accipitres hitherto dealt with in the present communication. Even the ileo-duodenal ligament is a little more extensive than it is in *Astur* &c.

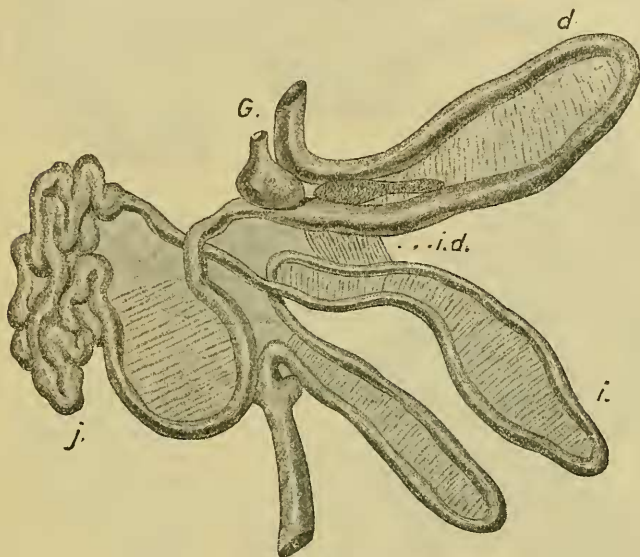
In *Tinnunculus alaudarius* there is an exaggeration of the "abnormality" of the duodenal lobe, which is almost bent upon itself in a spiral fashion. In this Hawk the greater part of the jejunum is disposed in a temporary spiral coil; but the first part of the jejunum is in the form of a single loop, which is comparable to that figured by Mitchell in *Falco**, and which I have described above in *Harpyhaliaëtus*.

Spizaëtus bellicosus (see text-fig. 20) is another species upon which Dr. Mitchell had not the opportunity of reporting. It agrees with other Accipitres in its general characters, but there are some minor points of difference. Thus, the disposal of the jejunal is exactly what we find in *Harpyhaliaëtus coronatus*. This region of the gut commences with a very wide stiff loop and then passes into a loosely folded length of tube. The ileic loop is rather longer than the duodenal, and the supracæcal kink is developed into a loop nearly as long, the two together reminding us of the double ileic loop of the Cranes and even the Tinamous.

* In both of two examples of *Falco peregrinus* I have not seen a marked loop corresponding to this. The jejunum lay entirely or mostly in a rough spiral, which could be arranged in an irregular circulat fold.

I have dissected one example of the New World Vulture, *Gypagus papa*, whose intestinal tract I am able to compare with that of *Cathartes aura* described by Mitchell. In view of the fact that the American Vultures have been regarded by many systematists as being quite remote in their affinities from the Old World Vultures, indeed from the Accipitres generally, it is very important to bring together all contributions that are possible towards settling this vexed question. The duodenal loop differs from that of *Cathartes* and is, indeed, quite like that of *Falco feldeggii* figured by Mitchell*. The distal extremity is folded over

Text-fig. 20.

Intestinal tract of *Spizaetus bellicosus*.

Lettering as before.

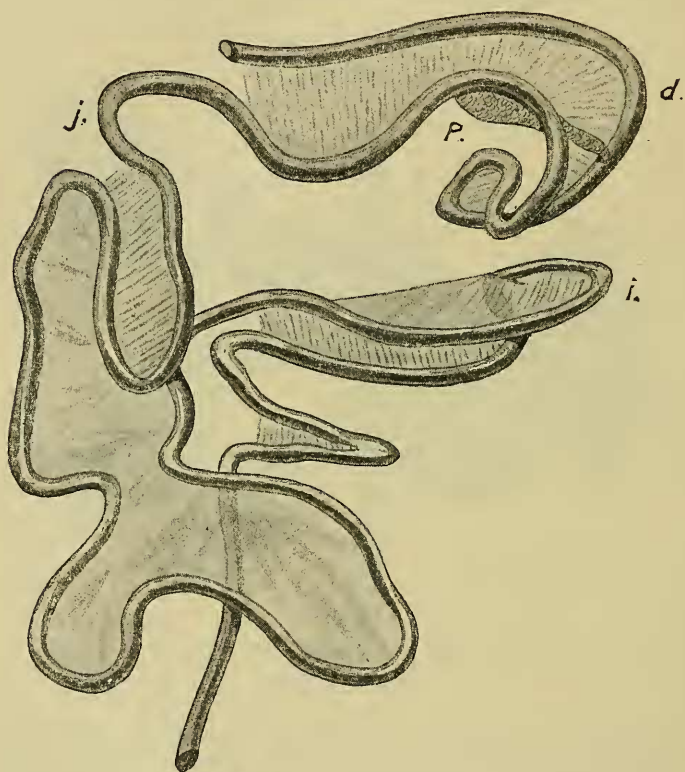
upon itself in a fashion that does not appear to occur among Picarian birds. The jejunal loop is arranged in a spiral fashion like many birds, including, however, *Tinnunculus*, in which *Gypagus* appears to differ from *Cathartes*. The ileic loop is simple. The kink so characteristic of Accipitres (but also found in other birds, including *Bucorvus*) above the position of the caeca in other birds is present as in *Cathartes*. It is not, in fact, possible to locate *Gypagus* definitely in the system.

I have also examined *Cathartes aura* (see text-fig. 21), and in most matters I am able to confirm Mitchell, as will have been

* Trans. Linn. Soc. t. c. fig. 33, p. 211.

inferred from what has been already said about *Gypagus*. The spiral of the duodenum makes rather more than a complete circle and its limbs are fixed together by mesenteries; the gut does not simply *lie in* a spiral. The loop which is lettered "*l*" in Mitchell's figure is broader and not so narrow according to my observations, but better marked than in *Gypagus*. As to the following portion of the small intestine, I do not agree in detail with Mitchell.

Text-fig. 21.

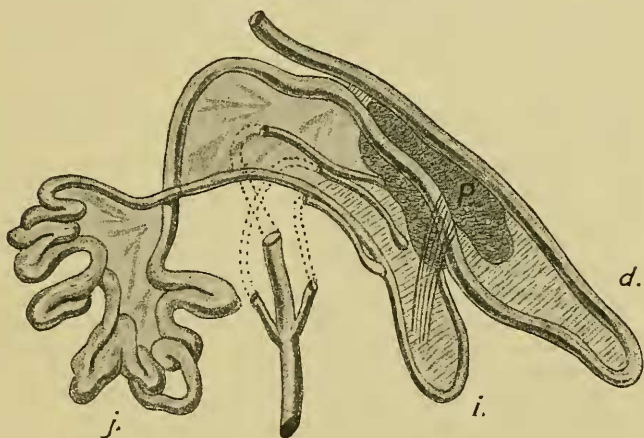
Intestinal tract of *Cathartes aura*.

Lettering as before.

The two loops forming it run close together, so that it is long and narrow, and not broad as figured by Mitchell. There is a tendency to form a rough kind of spiral not nearly so marked as in *Gypagus*. The ileic loop is only attached to the duodenal by mesentery at its very base. The supracæcal loop is more marked than in *Gypagus*.

STRIGES.—Among the Owls, I have examined *Scotopelia bouvieri*, which has not yet been investigated from the present point of view. The duodenal loop is widish and there is no trace of an ileo-duodenal ligament—in fact, the ileic loop lay on the right side of the body. The ileic loop is quite simple and is about as long as the duodenal. The jejunum shows three quite distinct loops; the first of these, *i. e.* that immediately following upon the duodenum, is wider than, but of about the same length as, another short loop which immediately follows it. A third loop of greater length has a distinct hint of spiral twisting. In *Syrnium aluco*, *Asio otus* (see text-fig. 22), *Strix perlata*, *Ninox boobook*, *Bubo maximus*, *B. virginianus*, *B. maculosus*, *B. cinerascens*, and *Strix flammea*, the ileic and duodenal loops are connected by a ligament which extends about halfway along the former loop. The difference is rather extraordinary in the matter of this ligament between *Scotopelia* and other genera, and it is, of course, possible that we have to do with an individual variation of *Scotopelia bouvieri*.

Text-fig. 22.

Intestinal tract of *Asio otus*.

Lettering as before.

The division of the jejunal tract of the small intestine into separate loops is not always well marked. In *Bubo maculosus*, for example, there are no fixed folds whatever between the duodenal and ileic loops; the whole of the jejunal region is like that of the Gallinaceous birds or the Mammalia, and can be passed through the fingers in a straight line without rupturing or even straining the mesentery. The same statement applies to *Bubo cinerascens*, of which species I have dissected two examples. I noticed here that the undisturbed jejunum lay in slight spiral coils; but these were

in no way permanent structures, but could be readily pulled out straight. In *Bubo virginianus* the greater part of the jejunum lies in the same way in loose movable coils; but there is a hint of a fixed loop—wide and shallow—at the commencement of the jejunum. *Bubo capensis* (I have seen two examples) and *B. maximus* were quite like *B. maculosus* and *B. cinerascens*, a slight and quite unfixed spiral being particularly noticeable in the case of the first-mentioned species.

I quite agree with Dr. Mitchell that *Strix flammea* has a jejunum which may be regarded as archicentric. I cannot, however, understand why Dr. Mitchell should emphasise the archaic character of the gut of this Owl by terming it “remarkably archicentric” and by figuring a state of affairs* which is not at all archicentric. For, in his figure of *Strix flammea*, there is correctly represented a well-marked “supraduodenal fold”—or ileic loop, as I prefer to call it—and a definite loop in the jejunal region. The latter I did not find in that species of *Strix*; but I am not at all disposed to dispute the accuracy of Dr. Mitchell’s figure. For in *Strix perlata*† the jejunal fold is disposed in three more or less equisized and not very close loops; but still they appear to be definite loops, and the jejunum is not merely a loose coil as in *Bubo*. This species is therefore not at all archicentric.

The conditions seen in *Strix perlata* seem to me to be a slight exaggeration of those which I noticed in *Strix punctatissima*. In the latter Owl the jejunum is formed by a tube which lies in the undisturbed intestine as a spiral. It can be smoothed out without tearing any mesenteric connections into the not circular but rather W-shaped coil so characteristic of Passerine and many Picarian birds; the rest of the small intestine is of less calibre and becomes suddenly so; it again lies in the body in a spiral fashion, but can be smoothed out in the same way into a broad but rather irregular ileic loop. The ligamentum ileoduodenale extends nearly to the end of this and is attached to about halfway down the duodenal loop. The pancreas extends for rather more than halfway down the duodenal loop. The gut of this genus is considerably shorter than in, for instance, *Bubo*, and is to be contrasted by its stiffness with the lower coils of the latter.

Athene noctua, being a small species, might be expected to show those differences from other Owls which are often met with in comparing small species with larger allies. As a matter of fact, the jejunal region of the gut is comparatively short and shows no trace of any fixed loop such as occurs in some other Owls. In this species the pancreas extends to the very end of the duodenal loop; in a species of *Ciccaba*, in *Strix flammea*, *Asio otus*, *Ninox boobook*, *Bubo maculosus*, *B. cinerascens*, *B. virginianus*, and some other Owls, the pancreas does not extend so far

* Trans. Linn. Soc. t. c. fig. 66, p. 248.

† It is not certain how far these alleged species of *Strix* have that value.

down the duodenal loop, but it is longer than in the Accipitres. This fact, indeed, and the rather greater extension of the ligamentum ileo-duodenale, is the chief difference that distinguishes the Owls from the Accipitres, the general plan of the gut in these two subdivisions of birds being otherwise similar in many ways.

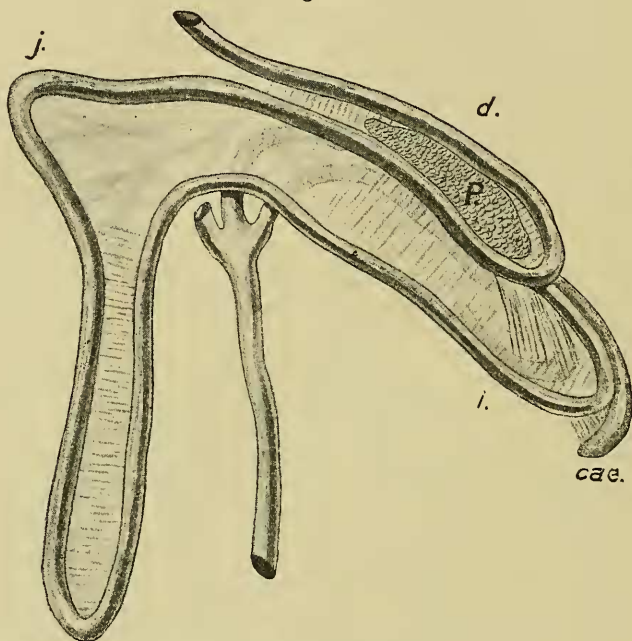
The groups that have been hitherto considered, viz. the Ratitæ, Galli, Hemipodii, Picopasseres, Cuculi, Musophagi, Accipitres, and Striges, agree with each other in that the jejunal region of the gut, though it may vary greatly in length, is never thrown into much marked fixed loops, such as those which characterise the groups of birds that remain to be dealt with. There is, indeed, the commencement of the formation of such loops to be seen in the Accipitres and Striges; but they do not arrive at the perfection and complexity of interconnection which is exhibited in the remaining families of Birds. Among the latter, however, with which I shall proceed immediately to deal, there are species and even genera which show the simpler conditions of the jejunum that characterise the families of Birds already dealt with—for instance, in *Pluvianus* among the Limicolæ and in the Bustards and Cariamidæ. In the latter the simple conditions look like reduction; while in *Pluvianus* we may have to deal with an archaic representative of its family which has not yet cast off the comparatively primitive type of gut.

ALECTORIDES.—The Bustards are an example of a well-marked family of birds which show a great uniformity in their intestinal tract. The species which I have myself examined are *Eupodotis australis* and *Houbara macqueeni*, and they evidently agree with *Otis tarda* as described by Mitchell*. In *Houbara macqueeni* the duodenal loop is attached to the ileic by a ligament which extends to the very end of the former; the ileic loop is considerably longer than the duodenal. The pancreas extends as far as the very end of the duodenal loop. The jejunal region is formed of a single fixed loop, which is not quite so narrow as is depicted in *Otis tarda*. *Eupodotis australis* (see text-fig. 23) has an intestine which is so like that of *Houbara* that I can find no fresh terms in which to describe it. Of birds admitted to be possibly allied to the Bustards, that which most closely resembles the two genera just referred to is *Chunga burneisteri*. The resemblance, however, does not quite reach, though it very nearly approaches, identity. In this bird the duodenal loop is, as in the Bustards, shorter than the ileic. But the ileo-duodenal ligament stops about halfway along the duodenal loop, though extending further along the ileic. A point of likeness to the Bustards is the extension of the pancreas to the end of the duodenal loop. The jejunal region of the gut is also like that of the Bustards, in that it consists of but one loop which occupies the whole region, of which, in fact, this section of the intestine solely consists. Here we have an obvious

* Trans. Linn. Soc. t. c. p. 226, fig. 45.

likeness to the Bustards. The loop differs, however, in being considerably wider than it is in the Bustards. These birds form together a part of Mr. Sclater's Order Alectorides, and, as they obviously agree together very closely in the characters of the gut, I deal with these provisionally under that name; for there is, at any rate, no very general agreement as to their position among related groups and their affinities with each other.

Text-fig. 23.

Intestinal tract of *Eupodotis australis*.

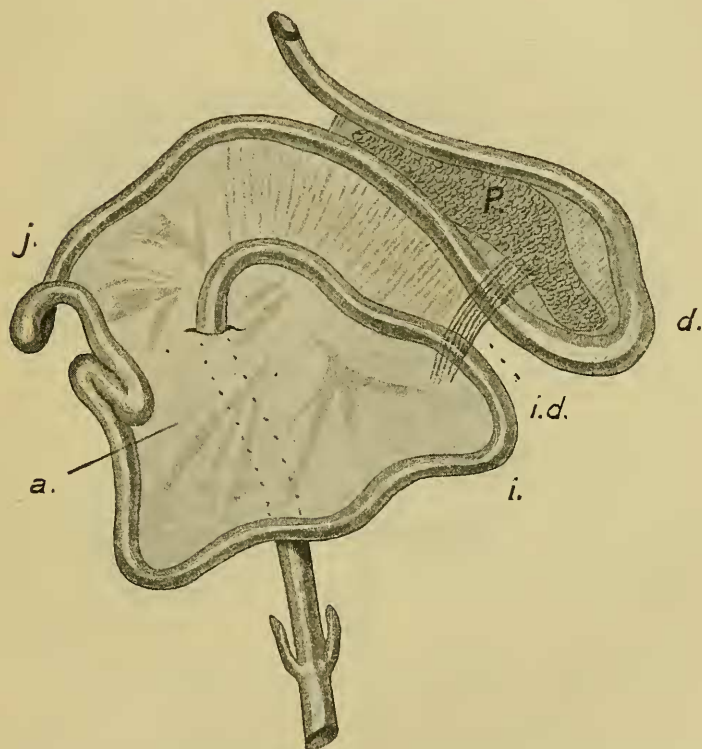
Lettering as before.

Among the LIMICOLÆ, with which, as I think, the Gulls and Terns are obviously to be placed, there are several variations to be seen in the coils of the alimentary tract. The most primitive form of the alimentary tract known to me among those birds is shown in the case of *Pluvianus ægyptius*, for reasons which I shall indicate after describing the facts. The duodenal loop is fairly wide and the pancreas extends back to the very end of that loop. The jejunum is not definitely distinguishable from the ileum, but the whole length of the small intestine, before it bends upon itself to form the straight region which bears the small and Passerine cæca, is loosely disposed as in Gallinaceous birds. The last part of this jejuno-ileic region runs, as in Gallinaceous

birds, parallel with the duodenal loop and is attached to it by an ileo-duodenal ligament, which extends nearly to the end of the duodenal loop. It is, as I think, possible to interpret this intestinal tract in only one way, and that is as follows.

It has been compared with that of a Gallinaceous bird, and this is really tantamount to saying that in the coils of the intestinal tract *Pluvianus* presents us with archaic characters. After the duodenal loop there is no marked differentiation of the gut

Text-fig. 24.



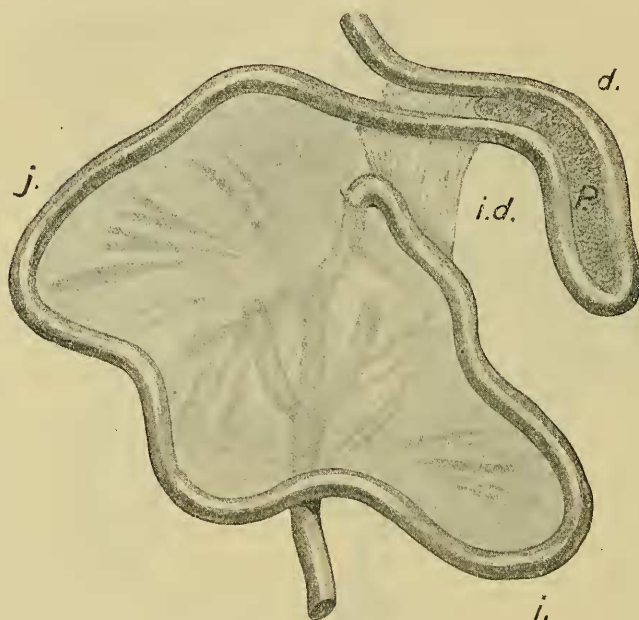
Intestinal tract of *Pluvianus aegyptius*.

Lettering as before.

into special loops at all. There is, however, as it appears to me, an indication of an advance upon the condition of the gut which characterises the Gallinaceous birds and in the direction of some other Limicolous birds. In the Gallinaceous birds the distal extremity of the small intestine is straightened out, but it is relatively only a small part of the jejuno-ileum which is thus

differentiated from the much longer coiled region. Now, in *Pluvianus* the distal portion of the jejuno-ileum can be *de rigueur* divided off from the point lettered *a* in the figure (text-fig. 24), after which point the intestine exhibits no resting in loose folds, but passes in a broad curve to the point where it is attached by a ligament to the duodenum. We have, in fact, here the commencing separation from the jejunal region of a very wide ileic loop. There is, in fact, a close similarity with the gut of *Melanerpes* *. A slight alteration in the gut of both of these

Text fig. 25.

Intestinal tract of *Edicnemus scolopax*.

Lettering as before.

birds leads to that of many Picopasserines, where the ileic loop is more definitely marked off from the jejunal but remains very broad. From this type, moreover, can be readily deduced the plan of intestinal coiling which is found in some other Limicolous birds which I have examined. One of the simplest of these is *Sarciophorus pectoralis*, in which the ileic loop is attached to the duodenal for nearly its whole length by the usual ligament and is also a wide loop. The jejunal has no fixed loops, but lies

* Vide p. 62.

in rather stiff coils, which approach a spiral; there are about three of these, so that the gut is not long. It is quite difficult to differentiate this gut from that of most Picopasseres. *Edicnemus* (*E. scolopax* and *E. grallarius*) hardly differs from *Sarcophorus*. Of this genus I may, in the first place, remark that the pancreas extends back to the very end of the duodenal loop. The attachment of this loop to the ileic is as in *Pluvianus*. The ileic loop, moreover, at any rate in *Edicnemus grallarius*, is very wide, another point of likeness to *Pluvianus* and, indeed, to other Limicolous birds that will be mentioned presently; indeed, in *E. scolopax* (see text-fig. 25) a separate ileic loop can hardly be defined—this character, in fact, is of the group. In both species of the genus *Edicnemus* that I have examined the jejunum lies more or less in a spiral, which is most marked in *E. grallarius*, though it is only a short spiral of one complete turn even in that species. It is particularly to be noted that this spiral, like that of Passerine birds, is not a permanent spiral, but that it can be pulled out to form an irregular circle without tearing any mesenteries. The genera which have just been dealt with are, in fact, not far removed from the common ground-plan, and the steps of differentiation are quite as is found in the great division of the Picopasseres. A further stage of differentiation is seen in *Recurvirostra avocetta*. Dr. Mitchell has correctly commented upon the spiral formation of the middle part of the gut, the jejunal region of the nomenclature adopted in the present paper.

This bird shows the typical Limicoline characters in (a) the fact that the pancreas extends to the very end of the duodenal loop, (b) in the wide ileic loop, which is about as long as the duodenal, and (c) in the extent of the ileo-duodenal ligament. The spiral is a fairly regular one, and although certainly not longer than, and, I think, hardly as long as, that of the Raven, differs from it in the important fact that it is a permanent spiral. The several coils are, indeed, connected together by mesentery and cannot be separated out without tearing this mesentery. What is a temporary character in the more archaic forms of gut has here become a permanent feature.

The LARI of Dr. Gadow's classification, which I myself prefer to associate more closely with the Limicolous birds, have an intestinal tract which entirely justifies the latter placing. I have examined *Larus ridibundus* and *L. argentatus* among the Gulls. In *L. ridibundus* the pancreas, as in Limicolous birds, extends to the very end of the duodenal loop. The ileic loop is also wide and is attached for the greater part of its length by the ileo-duodenal ligament to rather more than the first half of the duodenal loop. The whole of the jejunum, which is rather long, lies in loose folds like the Mammalian small intestine, with no fixed loops at all. I could not see any trace of a spiral arrangement in this specimen. In *L. argentatus*, however, the jejunum lay in a biggish loose spiral, which was not in any way permanent. There is, in fact, no difference between these two species of *Larus*.

In both, it should be added, there was a distinct supracæcal kink.

I have dissected two examples of *Sterna fluviatilis* which agree absolutely in the characters of their gut. This genus—also like *Larus*—is very definitely like the Limicolous birds. The pancreas, as in those birds, extends back to the end of the duodenal loop. The ileic loop is wide and of about the same length as the duodenal and, finally, the ileo-duodenal ligament is extensive and reaches nearly to the end of the ileic loop in the one case, and for more than halfway along the duodenum in the other. The jejunum lies in a rather short spiral of not more than three circles; the coils of the spiral, however, are not so fixed as in *Recurvirostra*, they can be pulled apart and arranged in about three loops. This state of affairs has been figured by Dr. Mitchell for *Sterna hirundo*, and his figure would fit perfectly the conditions which I found to characterise *Sterna fluviatilis*. There is also a supracæcal kink.

The Auks are associated by some with the Gulls*, but by others they are regarded as forming a distinct assemblage† or are associated with the Grebes and Divers into one group Pygopodes‡. An examination of the intestinal tract of *Fratercula arctica* (text-fig. 26) leads me to reject the former view and to hesitate between one or other of the two latter classificatory schemes. At the same time, it must be added that there is room for divergence of opinion in the interpretation of certain of the loops, as will be seen from the following account, in which I am unable wholly to confirm Dr. Mitchell's account. The duodenal loop is not in any way remarkable and quite unfolded. The pancreas extends nearly, or in one specimen quite, to its end. Thereafter follow two loops, which belong to the middle (jejunal) region of the gut. These are set more or less at right angles to each other; but the direction of the loop is, as I think, of less importance than the fact that there are two of them (and two only), which are roughly equal in size and very distinct.

Moreover, these two loops are interconnected by mesenteries. It is obvious that we have here a close resemblance to the Grebes, *Tachybaptus* and *Podiceps*§, and to those birds only among those whose anatomy in this respect is known. After these follows a large ileic loop, which is different in structure to that of many birds. Mitchell figures it as a simple wide loop. It is, however, long and irregularly looped, and longer than the duodenal loop. It appeared to me that it ended in two prolongations at its blind end, in which case there is an obvious comparison possible with the ileic loop in *Podiceps cristatus*||, which is loosely folded at its blind extremity. The small intestine before the cæca is thrown into another loop, which Dr. Mitchell has duly noted and has

* *E. g.*, Mitchell, *loc. cit.*

† *E. g.*, Beddard, 'The Structure and Classification of Birds': London, 1898.

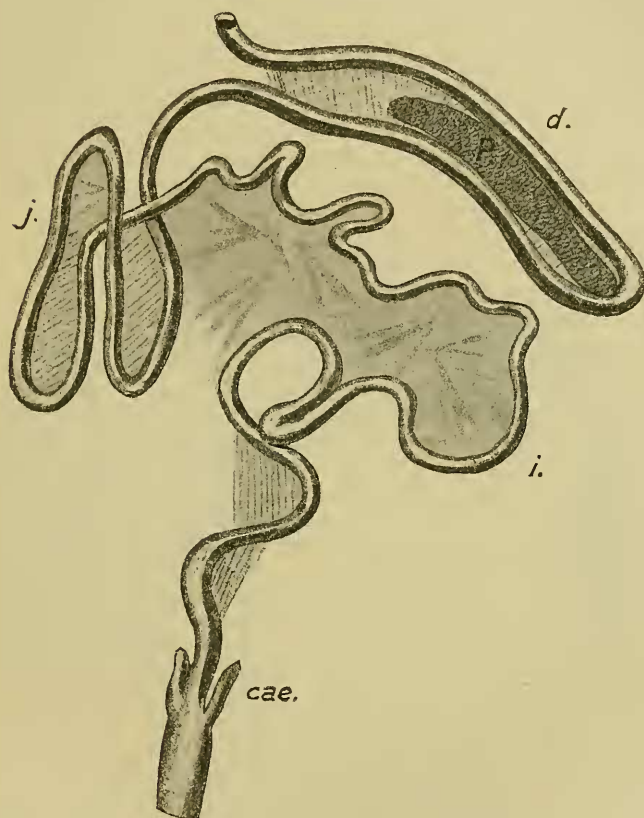
‡ *E. g.*, Vertebrate List Zool. Soc. Lond. 1896.

§ See below, p. 81.

|| See p. 81.

identified with that short loop which he has termed the "supra-cæcal kink." In a second specimen, all these characters were quite as plain, so that it cannot be held that the first individual was in any way abnormal. Probability, at any rate, indicates this conclusion. A third example, a quite young and immature bird, presented some slight differences which led me at first to suspect

Text-fig. 26.

Intestinal tract of *Fratercula arctica*.

Lettering as before.

a non-identity of species. I am assured, however, that this suspicion is wrong. The only difference concerned the two jejunal loops. Of these the first, *i. e.* that immediately following the duodenum, is much shorter than the second or more distal loop. The latter, instead of being a simple loop equisized with the first loop, is much longer and has a kink, or sudden flexure

to one side, in the middle of its course. It looks, in fact, as if two originally distinct loops were in process of reduction to one. The consideration of this specimen, therefore, renders another comparison possible, namely with the Cranes*, for in these birds the jejunum has three separate loops. In other respects, the third example of *Fratercula arctica* agreed entirely with the other two. Apart from possible resemblances to other groups of birds that have been indicated, the gut of *Fratercula* shows a feature of particular interest in the great length and irregular disposition of its ileic region. This latter is quite unattached to the duodenal loop, except perhaps at the very base; it is long and lies loosely coiled like the Mammalian small intestine. It is, in fact, the longest section of the gut. This bird, in fact, shows an intestine constructed in a way which is exactly opposite to that which is prevalent in the class Aves. When there are tracts of primitive undifferentiated small intestine left it is nearly always the jejunum that is involved, and not the ileic region. In *Fratercula* the jejunum is specialised into fixed loops, while the ileum has remained unspecialised. Indeed, my experience of this structure among birds has only furnished one example at all parallel to the gut of *Fratercula arctica*.

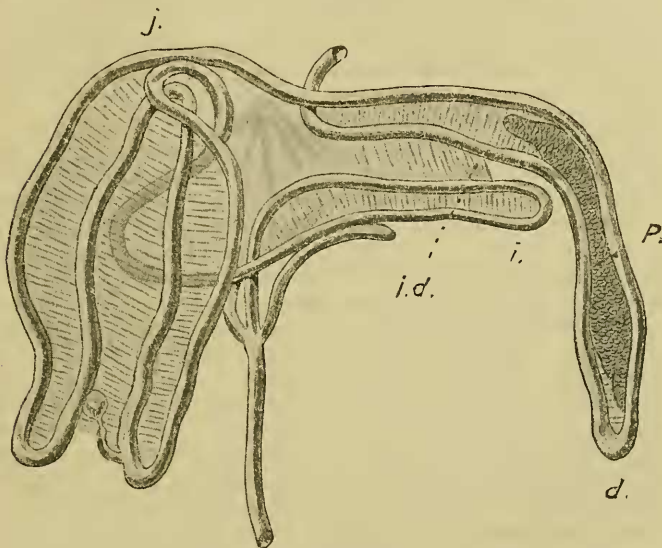
This was an example of the Pheasant, *Euplocamus nycthemerus*. The Gallinaceous birds (see p. 55) are very uniform in the disposition of their intestinal tract, and one out of two examples of this species which I have dissected was perfectly normal in the structure of the gut. A second individual, however, differed. The duodenal loop was immediately followed by a straight, stiffly fixed, descending tube of intestine, which bent back upon itself for a short distance and then passed into a long loosely coiled region, a kink became continuous ultimately with the straight portion of the ileum running to the junction with the caeca. This coiled region of the gut, although lying on the left side of the body, was not in any way attached to the duodenum. There is, therefore, here, it will be seen, a reversal of the conditions found generally among Gallinaceous birds. In this example of *Euplocamus nycthemerus* the stiff descending intestine which immediately follows the duodenum obviously represents in one sense the equally stiff ascending piece of intestine which is in the other example of *E. nycthemerus*, and also in other Gallinaceous birds, parallel to and partly fixed by ligament to the duodenal loop; while in the latter the loose coils which form the major part of the small intestine lie to the right hand. There is, in fact, a precise reversal of the "normal" conditions. There is, as I think, an undoubted resemblance between this "abnormal" example of *Euplocamus nycthemerus* and the normal arrangement of the intestinal tract in *Fratercula arctica*.

PODICIPEDES.—I cannot quite explain by means of Dr. Mitchell's figures the intestinal loops of the two Grebes *Tachybaptus*

* *Vide* p. 82.

*fluviatilis** and *Podiceps cristatus*†, of the former of which species I have examined two examples. The plan of the intestinal tract in the Grebes is very distinct and unlike that of any other birds that I have studied. In *Tachybaptus* the duodenal loop is considerably longer than the ileic (the precise reverse of the conditions obtaining in the Parrots), and the two are attached by a duodeno-ileic ligament which extends about halfway along the ileic loop (see text-fig. 27). I find only two jejunal loops (Mitchell figures four—two long and two short, exactly as in *Ara ararauna*), which are long and closely adherent for the whole of their length. The inner of the two loops, that which is immediately connected with the ileic loop, bore in one specimen a Meckel's diverticulum, as is indeed figured by Mitchell. The cæca extend about halfway along the ileic loop.

Text-fig. 27.

Intestinal tract of *Tachybaptus fluviatilis*.

Lettering as before.

Podiceps cristatus conforms to the general plan seen in the last species, but differs in detail. The ileic loop is peculiar and folded upon itself in a way. If unravelled it would be longer than the duodenal loop, and thus differs from that of *Tachybaptus fluviatilis*, shown in the illustration (text-fig. 27). The extent of the ligament uniting this with the duodenal loop is much as in *Tachybaptus*. In the middle part of the intestine there are only two loops, as in

* Trans. Linn. Soc. tom. cit. p. 186.

† *Ibid.* p. 185, fig. 5.

Tachybaptus; Dr. Mitchell figures five. The two loops are wider than those of *Tachybaptus*, but in the same way connected with each other up to the very end. Like Dr. Mitchell, I could find no Meckel's diverticulum.

Among the RALLI there is apparently but little modification of the intestinal characters from genus to genus. Although I have not examined the actual species which Hunter has described, it is clear that his descriptions are in all probability perfectly correct. Of the "White Fulica [*Porphyrio albus*, Cuv.]" he writes*: "The duodenum passes down as usual, and then up, somewhat higher than at beginning, making a sweep backwards to the loins and commencing jejunum. This passes down on the right side, then up, making a fold upon itself; then a second fold, as also a third, which last is attached to the first fold: all these are parallel to each other. The intestine then passes down, more in the middle of the abdomen, further than the former three folds, along with the duodenum." This fully tallies in the number of loops with Dr. Mitchell's statement and with my own observations; these latter are, I think, worth mentioning in brief, since they further emphasise the uniformity of this group.

In *Hydroornis alleni*, *Rallus abbotti*, *Porphyrio melanonotus*, and *P. madagascariensis* the ileic and duodenal loops are pretty well the same length and are attached by a duodeno-ileic ligament nearly to the end of both loops. In all of these forms there are, as both Hunter and Mitchell assert for species examined by them, three loops only in the jejunal region of the gut. The last of these three loops is the shortest of the three in all of the species which I have just mentioned. In *Porphyrio* (both species) I found a very conspicuous Meckel's diverticulum, which, as Mitchell correctly represents, lies near the bottom of the middle loop. Finally, I may remark that this middle loop, at least in *Porphyrio*, is free from the other two loops (as John Hunter has stated), which are connected by mesentery.

Aramides ypecaha quite agrees with these other types and, as in *Porphyrio*, the pancreas extends to the very end of the duodenal loop. In this form also the first of the three jejunal loops is the widest, and Meckel's diverticulum occurs at about the middle point of the middle one of the three loops.

Among the GRUES I have examined among others *Anthropoides paradisea* and *Balearica*, which do not agree very closely in the nature of their intestinal convolutions with those of *Grus virgo*, as figured by Mitchell. In both these Cranes there are three, and only three, jejunal loops, of which the first (as correctly indicated by Mitchell) is much the widest. The two following are longer and of equal length. On the first of these close to the blind end of the loop there is (in *Balearica*) Meckel's diverticulum. Mitchell figures the ileic loop as trifid. I find that in both the Cranes and in *Grus japonicus* which I have dissected (see text-fig. 18, p. 65) the

* 'Essays and Observations,' p. 317.

ileic loop is a double loop, the two complete rather narrow loops being not quite equisized. *Anthropoides leucauchen* agrees entirely with the other two species, and in all of them the pancreas stops some way in front of the end of the duodenal loop. The existence of three separate loops in the jejunal region is obviously a point of similarity between the Cranes and Rails and of difference between the former and certain other "Alectorides," *e. g.* *Cariama*, Bustard.

STEGANOPODES.—The intestinal tract of a species of *Fregata* has been examined and reported upon by Dr. Mitchell, who, however, was not in a position to state precisely to which species his observations referred. I have examined an example of *Fregata aquila*, and have something to add to the facts enumerated by Dr. Mitchell. He figures and refers to two cæca. I found only one cæcum, which was short and sessile, upon the gut. The duodenal and ileic loops are simple and of about the same length. The pancreas extends only about halfway down the duodenal loop as in Birds of Prey, and the duodeno-ileic ligament is about co-extensive with the pancreas. The duodenum is also connected with the jejunal area by a ligament which I have not found in other birds.

The condition of the jejunal area is interesting when compared with that of other Dysporomorphous birds. It is, comparatively speaking, short, while that of Cormorants and Pelicans is long. This comparative shortness is mentioned by Mitchell, who, however, has not seized upon a difference of some significance, as I think it, which this bird shows from its allies.

In *Phalacrocorax* and *Pelecanus* (the only other genera which I have examined with reference to the matter now under consideration) the jejunum is disposed in a considerable series of closely applied regular fixed loops, as in Ducks, Storks, and some other birds. *Fregata* presents us with a stage anterior to this. There are no definite and regular fixed loops, but the whole jejunum can be disposed in an irregular circle with bulgings here and there. It is not a simple archaic jejunum, as in the Gallinaceous bird; but neither is it the much specialised jejunum of other Dysporomorphæ. It is hardly more advanced in the direction of its immediate allies than is the corresponding part of the intestine in an Eagle or an Owl.

The PSITTACI possess a complicated intestinal tract, which is, as I think, more correctly described by Owen than by Mitchell. For it is quite impossible to represent the various loops into which the intestine is drawn in these birds in the fashion adopted by Mitchell, as will be readily seen by a comparison of the accompanying figure with his illustrations of *Ara ararauna** and *Stringops habroptilus*†. Owen mentions the "packet of folds" which are alternately connected as shown in the text-figure appended, while Mitchell represents a series of loops sometimes bifurcate or trifurcate, though stating that they are "folded

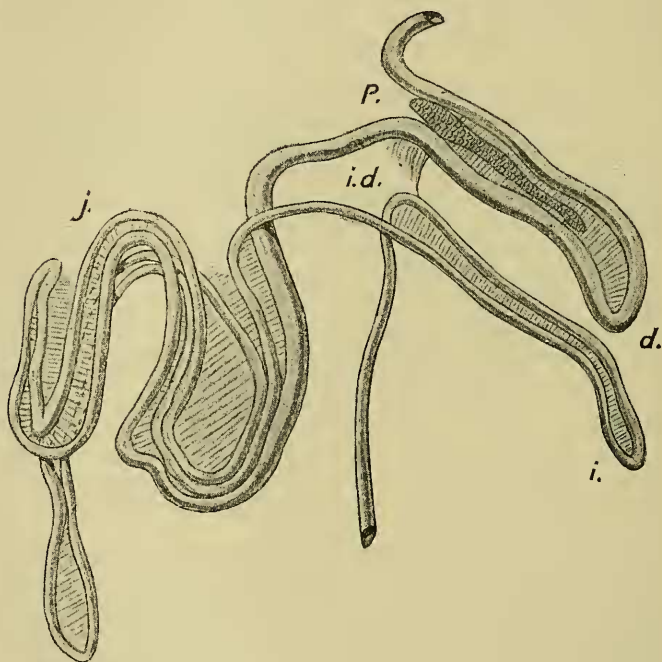
* P. Z. S. 1896, p. 155, fig. 21.

† Trans. Linn. Soc., Zool. (2) viii. p. 244, fig. 61.

upon each other, and twisted and doubled in a complicated fashion." It is easy to state the characteristics of the Psittacine alimentary tract, which in the species and genera *Ara ararauna*, *A. militaris*, *Nestor notabilis* (see text-fig. 28), *Chrysotis inornatus*, *Psephotus haematonotus*, *Callocephalon galeatum*, *Platycercus flaveolus*, *Cacatua sulphurea*, is constructed as follows.

The duodenal and ileic loops are single and elongated, as shown in Mitchell's figure. The jejunal loop consists of, proximally, a series of three loops one within the other, of which the ascending limbs of two are connected respectively with the duodenal and ileic loops, and, more distally, of two separate single loops longer than those of the proximal bunch, which are not directly connected with each other but with the loops of the proximal packet. The illustration will explain these interconnections better than a more elaborate description,

Text-fig. 28.

Intestinal tract of *Nestor notabilis*.

Lettering as before.

While there is in the species mentioned the general uniformity of structure which has just been explained, there are differences of small detail. Thus the two species of *Ara* differ, in that the proximal complex of loops in *A. ararauna* consists of only two

short loops, from which it follows that the two long loops inter-communicate directly. These facts, so far, are correctly shown in Dr. Mitchell's figure referred to. *Conurus leucotis* is precisely similar to *Ara ararauna*.

Melopsittacus undulatus is still further reduced. The proximal complex is, as in the last species, reduced to two, but there is only one of the two distal loops left and that is shortened.

On the other hand, *Eclectus pectoralis* is more complex than the forms already considered. Among this group of birds the ligamentum ileo-duodenale is rather short and the pancreas extends to the very end of the duodenal loop, or in some cases nearly so. The ileic loop is often considerably longer than the duodenal. It seemed to me to be particularly long in *Stringops habroptilus*, where it measured fully 8 inches in length.

Among the PIGEONS I have examined one or two forms not studied by Dr. Mitchell. This group contrasts, for instance, with the *Rallidæ* in the variety of intestinal patterns which it exhibits. This, it will be noticed, is in accord with variations in the group in other anatomical characters *. I propose, however, to deal with two genera in which the intestine has become shortened in relation to the fruit-eating habit, leaving other forms aside until I have been able to make a more comprehensive study. In one of these, *Ptilopus bellus*, the reduction in length, coupled with great increase in calibre, has not gone so far as in the genus *Carpophaga*, with which I shall deal later. In *Ptilopus bellus* the duodenal loop is quite well marked, though short and rather wide; the pancreas extends to its very end. The jejunal region which follows is also distinct from it and from the ensuing ileic loop. The jejunal region consists of a single loop only, the two limbs of which lie in close apposition, but can be considerably separated without tearing any membranes. This region of the gut is therefore, in consisting of a single loop without further complications, precisely like that of the Bustards and Cariamias. The ileic loop is also well marked and rather wide; it is much longer than the duodenal. The ileo-duodenal ligament is present, but not very extensive. There is also a ligament uniting the jejunal loop to the entering limb of the ileic loop for about halfway down the latter. The plan of the intestinal tract in this bird is therefore a rather primitive one, reminding us of that of *Otis* and *Chunga* and of the Picopassères. In fact, the degeneration of the intestine has resulted in the throw-back to a presumably earlier state of affairs.

The genus *Carpophaga* shows a further degeneration of the intestinal tract, which is well known to be very short in this genus of Pigeons †. The shortening is also accompanied by widening.

I have examined *C. ænea* and *C. concinna*. In both of these the duodenal loop has vanished and is represented perhaps by the

* Garrod, "On some Points in the Anatomy of the Columbæ," P. Z. S. 1874, p. 249.

† Cf., e. g., Garrod, "Notes on the Grizzard &c. of *Carpophaga latrans*," P. Z. S. 1878, p. 102.

slightest kink in the alimentary tube. The rest of the tube is disposed in four parallel and transversely arranged lines, which on further examination are seen to form a spiral and which end in a longitudinal section of gut running to the cloaca. I cannot distinguish in this a jejunal from an ileic region. It is interesting to compare with this "degeneration" of the intestinal tract in the fruit-eating Pigeons the corresponding alterations met with in the fruit-eating Passerine *Elurædus*. In that bird there is a vestige left of the duodenal loop, to the extremity of which the pancreas reaches. Indeed, the rest of the gut has retained, though in a reduced condition, the two recognisable divisions, of which the ileum is represented, as in the primitive Picopasserines, by a straight tract parallel with and connected by the usual membrane to the duodenal loop.

§ *Some General Considerations.*

The new facts which have been described in the foregoing pages give rise to certain reflections upon the affinities which they appear to indicate between different families of birds and upon the course pursued in the evolution of the gut of birds. The facts, so far as they are known, do not appear to me to lead to the establishment of a phylogenetic scheme, even of the evolution of the gut only, so elaborate in the setting forth of details as that which is drawn up by Dr. Mitchell as the result of his own labours in this department of anatomy. Nevertheless, it does seem possible to indicate certain stages in the evolution of the intestine, and here and there are indications, already to some extent considered, of affinities between different Avian families.

§ *The Primitive Form of the Intestine in Birds.*

It is obviously necessary, before considering the features which are the most primitive in the Avian alimentary tract, to get a clear notion of the essential differences which distinguish the alimentary tract of Reptiles from that of Birds; by this means we shall evidently arrive at the essential resemblances. Dr. Mitchell distinguishes the bird's intestine thus:—"It is distinguished from the intestinal tract of reptiles chiefly by the fact that the three divisions—the duodenum, Meckel's tract, and the rectum—are sharply marked off one from the other." These lines are written of *Palamedea*, which that author regards "as representing closely the ancestral type." It appears to me, however, that while *Palamedea* is undoubtedly an ancient type, the definition used by Dr. Mitchell is not a correct one. For, while in, at any rate, the majority of Lizards known to me there is a very marked distinction between the small intestine and the large, the Crocodiles show a further differentiation; for they show a very well-marked duodenal loop as well. The divisions of the alimentary tract therefore do not enable us to distinguish between Birds and

Reptiles. Indeed, in an earlier paper*, Dr. Mitchell has himself sketched in a perfectly correct fashion the alimentary tract from an Alligator, illustrating the facts to which I have just directed attention. From a gut like this it appears to me to be only just possible to distinguish that of *Casuarinus*† in its general characteristics, among which I do not include the well-developed cæca. The only difference that I can detect is a closer approximation between the ileic and duodenal regions in *Casuarinus*, already, however, marked, though to a less extent, in the Crocodilidæ, which, of course, foreshadows the very close association found in all other birds. This association, caused by the outgrowth of the long middle part of the small intestine from a short region of the primitively straight gut, naturally brings about the commencement of the formation of the fixed ileic loop, so conspicuous a character of the alimentary tract of other birds. It is most interesting to notice that among Crocodiles there is, in some species at least, a quite distinct ileic loop, related perhaps to this same association between the ileic and duodenal regions, which is not, however, as has been already remarked, so close among Birds. It is to be noted that here as elsewhere the closest association of Birds and Reptiles is shown, thoroughly justifying the views of Cope, Huxley, and others. It may be admitted, therefore, that *Casuarinus* is, at any rate, one of those birds whose intestinal tract, both arrangement and convolutions, hardly differs from that of Reptiles, and is therefore primitive as compared with that of many other birds. Nor, indeed, is there so far any very great difference from the most primitive form of the gut in Mammals, where, as in *Casuarinus* and *Crocodilus*, the entire intestinal tract is borne upon a continuous mesentery.

§ *The Course of the Evolution of the Gut.*

From the simple conditions which obtain in *Casuarinus* the more complicated intestinal tract of other birds can be derived; and an almost complete chain of intermediate stages is exhibited, even among the few genera which I have had the opportunity of studying. It is from this point that the characters of the intestinal tract in Birds diverge from those of Mammals, the Reptilian conditions being left behind by both groups of Vertebrates. It may be convenient at this stage to point out the essential differences which distinguish the intestinal tract of Birds from that of Mammals. It has already been pointed out‡ that one difference is to be seen in the fact that among Mammals the permanent loops of the large intestine distinguish that gut from the small intestine, where there are no such permanent loops; whereas in Birds it is the small intestine only which exhibits these permanent loops. These characters, however, though

* P. Z. S. 1896, p. 137, fig. 1.

† I have examined the species *C. rothschildi*, *C. intensus*, and *C. westermanni*.

‡ *E. g.*, Gegenbaur, *Vergl. Anat. d. Wirbelth.*

distinctive in the negative sense are not universal. There are whole orders of Mammals, *e.g.* Carnivora, Marsupials, Primates, Edentata, in which the colon has no permanent loops, while in many birds, *e.g.* Gallinaceous birds, certain Picopasserres, the small intestine has no fixed loops. In addition to this very important difference, there appear to me to be two other distinguishing features in the alimentary systems of the two orders, which are perhaps equally important and are certainly more regularly met with. In all Mammals above those few forms (*e.g.* certain carnivorous Marsupials, certain Edentata*), which have so far retained the Reptilian characters of gut, the whole intestine is rotated upon itself and the rotation is fixed and the change of position of the various sections of the gut retained by the ligamentum cavo-duodenale which moors the end of the duodenal loop to the colon, mesocolon, or median dorsal body-wall on or near the postcaval vein. This ligament correlated with the said rotation is universal among the higher and present in most of the lower Mammals. In Birds, on the contrary, there is no such tract of mesentery fixing the duodenum to the colon. So far, in fact, the bird's intestine has retained the primitive Reptilian condition. The bird's intestine, however, usually has what the mammal's intestine has not, a duodeno-ileic ligament. This doubtless is the physiological equivalent of the duodeno-colic ligament (as Mitchell† has pointed out), in so far as it serves to anchor the perhaps otherwise inconveniently long and coiled small intestine. It may also perhaps be argued from this that a short intestine (*e.g.* many Picopasserres) is shown to be a secondary state of affairs, from the very fact that it is in those birds provided with a duodeno-ileic ligament, which may not be a mechanical necessity. For the existence of the ligament in question may be due to mechanical needs in an ancestor with a long small intestine. In any case, the morphological fact is to be noted and it constitutes a real difference between the Mammalian and Avian gut.

In very nearly all birds whose intestinal tract is at or above the level of that of the Cassowary, the end of the small intestine‡ is attached by a mesentery of varying degree of development to the duodenum. This, without any further specialisation, is the first stage in the evolution of the gut from its simple archaic form. This stage characterises the hypothetical Gallinaceous birds in which it is universally present and quite similar in all.

This simple stage, which we may term *Stage A*, is also found in other groups, but it does not occur in all the members of any other group as it does in the case of the Gallinaceous birds. Among the Struthious birds, for example, we have it in the Cassowaries, Ostrich, and *Apteryx*§, whose intestinal tracts are

* For a general survey, see Klaatsch, *Morph. Jahrb.* xviii. 1892, and myself in *P. Z. S.* 1908, p. 568 &c.

† *Trans. Z. S.* xvii. p. 524.

‡ The chief exception known to me is furnished by *Fratercula arctica*, the remarkable characters of the intestine of which bird I have already commented upon (*supra*, p. 78).

§ The condition of *Rhca* requires perhaps further study.

precisely similar so far to that of the Gallinaceous birds. We have in certain Picopasserres (e. g., *Melanerpes*) the same state of affairs, coupled in this case with a considerable shortening of the gut. Among the Limicolæ the genus *Pluvianus* is also in this stage.

The next stage, which may be called *Stage B*, is like the last, save for the fact that the ileic loop is definitely formed. The jejunal region remains unspecialised. To this stage, we refer the gut in the majority of Picopasserres, including the Cuckoos and Plantain-eaters. The "Alectorides" (in the sense in which I venture to use that term in the present communication) seem, but perhaps only seem, to belong to this stage. Among the Limicolous birds *Sarcophorus* and Gulls appear to belong here. Perhaps we should also place in this assemblage the Dysporomorph *Fregata*.

Stage C is a slight advance upon the foregoing. It is exemplified in certain Owls and Hawks, where the ileic loop is fully differentiated off and attached in the usual way to the duodenum, and where the jejunum is largely laxly coiled without any definite loops, save a single loop, and that not a very well-marked one, which occurs at the commencement of the jejunum. I have not noticed this kind of intestine in any other group, except the Nocturnal and Diurnal Birds of Prey.

Stage D might possibly be further divided up, but for the present I do not see a clear way through the great variations which the intestine of the more complicated forms shows. In all of them the jejunum has become differentiated into fixed loops, which vary in number, in relative length, and in their relations one to the other. The majority of the larger birds belong to this stage, as, for instance, the Cranes, Rails, Ducks, and Storks.

§ *The Mutual Affinities of Avian Families judged by the Intestinal Convolution.*

The known facts do not, as I think, permit of any complete scheme of classification of Birds by means of the variations in the coils of the intestinal tract. Here and there, however, there would seem to be such indications, which are tolerably well marked. More frequently, however, either a general plan runs through a series of two or three groups, which makes any definite placing of these groups in reference to each other difficult, or a complete isolation is shown. The most salient instance of the latter conclusion is undoubtedly the group of Parrots, whose intestinal coils are constructed upon a plan which is apparently universal in that group, but totally unlike anything which is to be found in any other group. The affinities of the Psittaci have been very variously interpreted*, but it is clear that the gut does not enable one to decide upon any of these diverse views. I cannot at all agree with Dr. Mitchell in saying

* Many or most of these opinions are mentioned by Fürbringer in his monumental work, 'Untersuchungen ueber Morph. u. Syst. der Vögel,' Amsterdam, 1888.

that "the relation to the common type is, however, easily made out" *.

In the same way, the Ralli are a quite circumscribed group judged by their intestinal coils, which bear only a general resemblance to other groups and, indeed, to no group in particular. Their characters are constant throughout the group, so far as known facts enable us to make a statement. The most that can be said is, perhaps, that they are nearer to the Grebes than the latter are to any other subdivision of the Bird tribe. On the other hand, it seems to me to be quite clear that if judged by their intestinal coils the newer ideas with respect to the New World Vultures and other Accipitres† must be abandoned, as Dr. Mitchell has correctly pointed out; it is necessary to revert to the older view which regarded the Condors as merely Vultures. In the same way, although in this Dr. Mitchell does not agree with me, the older opinion as to the Owls, that which placed them close to the Accipitres and not in the neighbourhood of various Picarian genera, is most certainly justified by the close similarities in the mode of arrangement of the intestinal loops. At the same time, it is also easy to distinguish these two groups by the small but constant characters afforded by the ileo-duodenal ligament.

And, again, it is by no means possible to distinguish by characters that carry any conviction the intestinal tract of a Grebe or Tern from that of the Owls on the one hand or large Passerine birds on the other; while the Gulls and Terns on their side offer resemblances to what I venture to term "the other" Limicoline birds. Negative features are perhaps more salient in making a brief survey like the present. Thus it is clear that the Tinamous are quite unlike the Gallinaceous birds and that the genus *Turnix* is equally to be removed from that assemblage. The Bustards and Cariama, moreover, show no particular likeness to the Cranes, though the first two seem to be closely allied to each other, as I have already pointed out. It is noteworthy that all the four types‡ of Struthious birds differ from each other as much as would seem to be possible in view of the undoubtedly primitive characters of the gut in all of them, with the possible exception of *Rhea*.

§ *The Relationship between the Gut and the Nature of the Food.*

When we contrast the intestine of a Penguin with its enormous series of closely adpressed straight loops and the intestine of a Bustard with only three short intestinal loops, there would appear to be a very marked difference between a fish-eater and an omnivorous bird, and thus a close relationship between the form and length of the gut and the nature of the food eaten by its

* P. Z. S. 1896, p. 155.

† These opinions are so well known that I need not quote what would have to be a long list of books and memoirs.

‡ *Casuarus* and *Dromæus* belong, of course, to the same type.

possessor. There is not, however, in all cases a relationship which is plainly to be recognised between differences in diet and differences in the intestinal part of the alimentary tract, and on the other hand a totally different diet sometimes coincides with a close similarity in the intestinal convolutions. Phylogenetic relationship appears to me to have much more to do with these similarities and differences in the gut. Furthermore, the way in which the intestinal tract is modified in accordance with the diet, when it does appear to be so modified, seems to have pursued a different path in different groups in some cases. Of fish-eating birds, for instance, the general idea is that the gut is long, and that undoubtedly is the case with the Penguin and the Cormorant-Pelican group. But then in these groups no representatives are known which are not fish-eaters. Directly we come to the consideration of groups of birds which contain fish-eating genera and genera whose food is not fish, we are sometimes met by a totally different state of affairs.

According to the statistics collected by Mr. Newstead*, the Terns (of three species) are exclusively fish-eaters. Yet their gut is not markedly and indeed hardly at all different from that of the Avocet, which devours aquatic insects, and some other Limicolæ which select a similar diet. The Kingfisher (*Alcedo ispida*), which is, according to the same authority, practically entirely a fish-eater, has a gut which is very like that of the omnivorous Corvines, and has, moreover, a much shorter spiral jejunum than in the differently feeding *Haleyon sancta*. The Toucans† are mainly fruit-eaters, though, like so many birds, they will vary this diet with animal food. And yet their intestinal tract differs very little from that of *Podargus*, which is presumably not at all a fruit-eater, but subsists entirely upon insects and other animals. Again, the Touracous‡ are fruit-eating birds; but their gut is like that of a vast series of Pico-passerine birds which feed upon all kinds of food.

In asserting that the gut is short in all purely frugivorous and insectivorous birds, Dr. Gadow practically admits how little stress can be laid upon the relationship between length of gut and the nature of the food. For the nature of the diet in each case is as different as possible. Nor can any general principles be stated as to the complication of the gut in families of birds which live differently. Thus the plan of the gut in *Apteryx* is practically identical with that of the Gallinaceous birds, and the character of the food differs. On the other hand, the pattern of the gut in Accipitrine birds is not dissimilar to that of Owls, and here we have a general similarity in diet. It is, in fact, not possible to lay down general rules which have not copious exceptions. Many of these exceptions can be gathered from the foregoing pages.

* Supplement to the Journal of the Board of Agriculture, vol. xv. No. 9 (1908).

† Newton, 'A Dictionary of Birds' (London, 1893), *sub voce* "Toucan."

‡ *Id. ibid.*, "Touracou."

§ *Id. ibid.*, "Digestive System."

§ *Summary of Facts relating to the Intestinal
Coils of Birds.*

We are in a position, I think, to lay down with confidence the following general statements with regard to the intestinal tract of the Class Aves. These statements are deduced from the memoirs of others who have written upon this subject, as well as from the facts ascertained by myself, and embody in a brief form what is known upon the subject dealt with in the present communication:—

(1) There are no essential differences between the intestinal tract in Birds and in Crocodilia. The most complicated alimentary tract in Birds can be derived through a series of stages from the simple Crocodilian form.

(2) The intestinal tract of Birds differs from that of Mammals in that there is never in the former, as there is generally in the latter, a rotation of the gut coupled with an attachment of the duodenum to the colon or mesocolon by a duodenal caval ligament. On the other hand, there is nearly always in Birds an ileo-duodenal ligament which serves to hold together the gut and which is wanting in Mammals. Furthermore, in Mammals the colon may be specialised into fixed loops, while in Birds such fixed loops are found only in the small intestine.

(3) The small intestine of Birds can, with rare exceptions, be distinguished into duodenal, jejunal, and ileic regions.

(4) The duodenal region consists of a long well-defined loop (only absent in certain fruit-eating Pigeons), which is usually straight, but sometimes (*e. g. Milvus*) shows indications of—or a pronounced—spiral arrangement, as it does also in certain Crocodilia. It is wider or narrower in different groups, and the enclosed pancreas extends a greater or a less way towards the extremity of the loop in different birds.

(5) The jejunal region is sometimes (*e. g.* Gallinaceous birds) marked off from the duodenal by a sudden diminution in calibre. It is usually the longest section of the gut; but is sometimes as short or even shorter than either the duodenal or ileic region or both. It may be a tract of intestine without any fixed loops (as in the Gallinaceous birds, various Passerines, &c.), but if of considerable length is usually specialised into a series of two or more fixed narrow loops, which may be interconnected by secondary mesenteries in different ways, distinctive of different groups of birds. An intermediate condition is seen (*e. g.* among Accipitres and in *Fregata*), where the jejunum is not arranged in lax and alterable coils as in the Gallinaceous birds, but is stiffened here and there into wide loops, which are not so sharply marked off as in the more specialised birds and are not interconnected by secondary mesenteries.

(6) The ileic region is not always quite distinct from the jejunal, and degrees of distinctness occur. In less specialised intestines there is no definite loop, but the end of the ileum is

attached for a variable distance by a secondary mesentery to the duodenal loop. In more specialised intestines the ileic region forms a distinct loop which is narrower or wider, and which is equal to, longer, or shorter than the duodenal loop, to which it is attached for a greater or less length by the ileo-duodenal ligament already mentioned. Not infrequently the ileic region consists of two loops, of which one is often small and lies just above the cæca.

(7) The plan of the gut is constant (except for very slight variations) in all the members of certain groups. This is the case with the Psittaci, Galli, Raptores, Striges. In the case of other groups, there are considerable divergences of structure within the group: this is the case with the Picopasseres, Limicolæ, Grues, Struthiones (if, that is to say, the two latter groups can be regarded as natural groups, which is open to doubt on other grounds).

(8) A comparison of the intestine of Birds with that of Reptilia (especially Crocodilia) allows of the recognition of more and of less primitive types of intestine. The most primitive type is found in the Cassowaries, *Struthio*, *Apteryx*, and all the Gallinaceous birds; and is also seen among the Picopasseres (Woodpeckers) and Limicolæ (*Pluvianus*). Most Picopasseres and the Birds of Prey (nocturnal as well as diurnal) show a rather more specialised form of intestine. In the remaining groups of Birds the intestine is more specialised still and in several different directions.

(9) Certain classificatory results seem to follow from a comparison of the differences exhibited by the intestinal tract. Thus, the resemblance of both Cuculi and Musophagi to the Picopasseres, and the likeness between all the Accipitres (New World and Old World, nocturnal and diurnal) are remarkable. The close likeness between the Bustards and the Cariamidæ is to be commented upon. The Passerine character of the gut of *Turnix* and the possible likeness between *Crypturus* and *Rheca* seem also to be shown.

7. On the Specimens of Spotted Hyænas in the British Museum (Natural History). By Prof. ANGEL CABRERA, C.M.Z.S.

[Received November 5, 1910: Read November 29, 1910.]

Every zoologist working on the Spotted Hyænas with suitable material from different localities feels the convenience of recognising several local forms. As early as in 1812, two of them were admitted by Cuvier, and in modern times no less than nine other "species" have been described. It is not easy to say with which form Erxleben's *Hyæna crocuta*, afterwards the type of the genus, or subgenus, *Crocuta*, must be identified, as the species was